The New England
Journal of Medicine

Copyright, 1949, by the Massachusetts Medical Society

Volume 241 AUGUST 11, 1949 Number 6

COMPLETE ACROMIOCLAVICULAR DISLOCATION

BOARDMAN MARSH BOSWORTH, M.D. (OXON.)*

BRONXVILLE, NEW YORK

FOR a lesion that appears to be so simple, complete acromioclavicular dislocation can be one of the least satisfactory of traumatic injuries to treat. It is rarely difficult to reduce the dislocation but to *hold* the reduction is another matter.

STRUCTURE AND FUNCTION

This problem is best approached by a brief consideration of the structure and function of the parts involved. In man, the upper extremity is not normally used for weight bearing but largely for prehension and tactile information — uses that require an extreme degree of freedom and as full a range of motion as possible. Such mobility is assured through an anatomic strut, the clavicle, which holds the scapula well out from the central body axis, acting somewhat as the boom of a derrick.[1] At the outer end of this strut the scapula, a relatively large and heavy bone from which the whole upper extremity depends, joins the clavicle through a single small and inherently weak articulation. The average acromioclavicular-joint surfaces measure only 1.9 by 0.9 cm.; the capsular ligaments are thin, and the joint is at an added mechanical disadvantage in that, in most cases, the articular surface of the acromion slightly underlies that of the clavicle.

Obviously re-enforcement is needed. It is provided by the dense, strong fibers of the coracoclavicular ligament, which occupy the 1.3-cm. space between the upper surface of the coracoid and the undersurface of the clavicle (Fig. 1). This ligament has no anatomic connection with the acromioclavicular joint, but it is essential to the proper functioning of that joint.[1-4] It is tough, but elastic and so arranged as to allow a small amount of motion in *all* axes at the joint; it should be noted that this includes some degree of rotation about the long axis of the clavicle.[1, 5, 6] However, as Codman[1] has emphasized, "All these motions are very slight in degree and. . . the range of the acromioclavicular joint is only the range of the pliability of the coracoclavicular ligaments themselves. . . ." Rarely, the ligament is replaced by a joint,[7-9] but this is of academic rather than practical interest.

PATHOLOGY

In essence, the coracoclavicular ligament serves as a short, stout cord by which the scapula hangs from the outer end of the clavicle. If that cord is disrupted (Fig. 2) the acromioclavicular joint will dislocate, the outer end of the clavicle will move up and back, the scapula, with the upper extremity, will drop downward, forward and inward, and the patient will be unable to abduct his arm. This is the picture of complete acromioclavicular dislocation, and it is imperative, when repair is contemplated, that attention be focused not on the dislocated acromioclavicular joint but on the torn coracoclavicular ligament.

Healing takes place here, as elsewhere in the body, by scar formation. If the torn ends of the ligament are maintained in apposition during the six to eight weeks that healing requires, firm re-establishment of ligamentous integrity is the rule. An interesting observation is the frequency with which calcification, and later ossification, occurs within and about the torn ligament.[10-12] Whether this is due to hemorrhage or detachment of periosteum, or both, is a matter of conjecture. Apparently, it is an interesting pathological finding that is unrelated to the type of treatment used and, fortunately, has no adverse effect upon function or cosmesis.[11-13]

Partial dislocation of the joint occurs when the capsular ligaments give way with little or no tearing of the coracoclavicular ligament; displacement is usually negligible, and the prognosis, with temporary external support, excellent. However, *complete* dislocation, which involves tearing of the coracoclavicular ligament, is the sole consideration here.

ETIOLOGY

Complete dislocation results from a severe blow impinging upon the acromion in such a way as violently and suddenly to depress it in its relation to the outer end of the clavicle. This occurs in one

*Associate attending surgeon, Grasslands Hospital, Valhalla, and Lawrence Hospital, Bronxville, New York; assistant attending surgeon, Mt. Vernon Hospital, Mt. Vernon, New York.

of two ways: either an object falls on the acromion or, more commonly, the patient falls and lands on the acromion.

Diagnosis

The distinction between partial and complete dislocation is an important one to make, since it affects treatment. The diagnosis of complete disruption is obvious in cases in which the tip of the clavicle lies free and high in the subcutaneous tissue, tenting and nearly perforating the overlying skin. In other cases the diagnosis may be difficult. The best criterion is roentgenographic evidence of a widening of the space between the coracoid process and the overlying clavicle on the affected side, as compared with the other, normal, shoulder[8] (Fig. 2). This may easily be demonstrated on a single roentgenogram, taken to include both shoulders, with the patient standing. I have not found it necessary to have the patient hold a heavy weight in each hand,[10] although this might be of assistance in some cases.

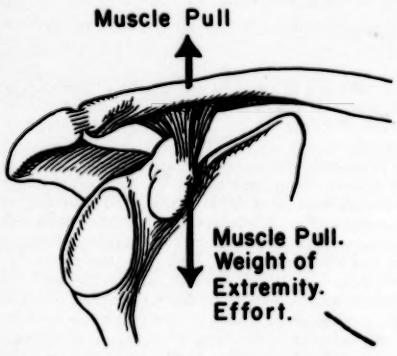

Figure 1. *The Coracoclavicular Ligament, a Short, Stout Cord by Which the Scapula Hangs from the Outer End of the Clavicle.*

Treatment

Forms of treatment suggested for complete acromioclavicular dislocation fall into two main groups, operative and nonoperative.

Nonoperative

This is an attempt to maintain reduction by externally applied pressure, or by traction, until healing of the torn coracoclavicular ligament has taken place. A review of the literature of the past decade reveals many methods aimed at accomplishing this result.

The procedures advocated include the following: adhesive (or other) strapping,[14-22] a figure-of-8 bandage, as for fractured clavicle,[23] sling and pressure dressing,[24, 25] a "suspension hammock" with a cradle under the axilla,[26] a brachioclavicular splint,[27-29] a thoracobrachial cast with pressure pad,[30-36] a thoracic cast with axillary crutch[37] and abduction traction and suspension in bed.[38, 39]

It is extremely difficult to compare results of these different methods for two reasons: careful studies of long-term end results are regrettably scarce, and many authors do not distinguish clearly between partial and complete dislocations.

Urist[35] recently presented a four-week follow-up study of 15 complete dislocations in young soldiers treated with the thoracobrachial cast and pressure pad. All were kept in the cast for six weeks and then had 2 weeks of physiotherapy. Among the 15 patients, there were 3 redislocations within four weeks, and in 2 of these cases symptoms were severe enough to require subsequent operative intervention. Thus, failure of conservative treatment was appreciable in a small but well controlled series of freshly incurred injuries in young healthy persons — all treated with the same nonoperative method by the same doctor. In an earlier paper Ehlert[24] reported excellent one-year to three-year results in 22 of 26 complete dislocations treated with a sling and pressure dressing. Howard[27] observed success in 8 out of 10 complete luxations treated with a brachioclavicular cast. Significant reports of end results obtained by the other conservative methods of treating *complete* acromioclavicular dislocations are lacking.

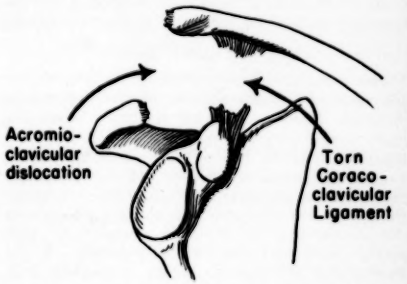

Figure 2. *Rupture of the Coracoclavicular Ligament, Resulting in Complete Acromioclavicular Dislocation.*

Operative Treatment

Three basically different surgical concepts have been followed in the treatment of complete acromio-

clavicular dislocation: excision of the outer end of the clavicle; fusion of the joint; and restoration of the joint.

Excision of the Outer Portion of the Clavicle

In the past few years this has been strongly urged by the late Fraser Gurd[40] for fresh injuries, by Mumford[18] for persistent pain and disability from chronic lesions, and by Urist[35] for both. It is not a recent innovation. Removal of a greater or lesser part of the distal clavicle, for this and other lesions, has been practiced for years with acceptable results. Gurd[2] reported 2 successful cases, Urist[35] 9 and Mumford[18] 4, but none of Mumford's patients had complete dislocation. In fact he recommended fascial suture in preference to clavicular excision for this lesion.

Fusion of the Acromioclavicular Joint

In 1943 Caldwell[41] reported 2 cases of chronic complete acromioclavicular dislocation treated by fusion of the acromioclavicular joint with good results at twelve months and five months, respectively. In both patients abduction was limited. No other author has recommended this method in the last ten years.

Restoration of the Acromioclavicular Joint

Restoration of the acromioclavicular joint to its normal anatomic and functional status should constitute the best treatment if it can be accomplished without serious harm or disadvantage to the patient. The difficulty of bringing this about satisfactorily, however, is amply attested by the introduction of the radical procedures just considered as well as by the great variety of reparative technics described in the literature, all of which fall into one or another of four fundamental groups: skeletal traction; syndesmopexy and ligamentoplasty; wire transfixion-fixation; and screw suspension.

Skeletal traction has few advocates. It may be applied in any one of several ways, but they all involve the very real danger of infection imposed by foreig.. bodies transfixing the skin for any length of time. This seems sufficient reason to condemn the method, especially since traction can be applied effectively without operation.[38, 39]

Syndesmopexy[42] and *ligamentoplasty*[3, 18, 43-51] may be considered together since they both aim at reapproximation of clavicle and coracoid process by suture material. In the former, foreign substances such as silk, wire and catgut are used, and in the latter autogenous fascia is employed.

Ligamentoplasty, certainly until recent years, has been the method most widely used in the treatment of complete acromioclavicular dislocations. It is subject to numerous modifications. A free graft of fascia lata or the coraco-acromial ligament[44] or a portion of the short head of the biceps brachii[46] may be used. These materials may be passed completely around the clavicle and coracoid or through drill holes in the bones. Reinforcement is usually provided with silk, cotton, catgut or wire sutures. In 1 case a coracoclavicular screw was used to reinforce a repair made with part of the short head of the biceps.[52]

Twelve good results with this repair have been reported by five different surgeons[42-46, 48] in the last decade. Serious complications, such as infection and sloughing of the fascia, are not mentioned. However, it is known that they sometimes occur.[52] Some surgeons supplement the operative repair with a cast for four to six weeks.[43, 44]

Wire transfixion-fixation was introduced by Gordon Murray[13] in 1940 with the report of 5 cases successfully treated with Kirschner wires inserted horizontally through the acromion, across the joint and into the clavicle.

Phemister[54] prefers heavy threaded wires, which are removed after two months. He immobilizes the arm and forearm for one month and the arm alone for an additional month in a Velpeau bandage. He does not permit shoulder motion while the wires are in place for fear of their breaking. He reports 2 cases with excellent results at four years and five months, respectively.

Bloom[55] used wire transfixion-fixation in 12 cases in the Navy, with results that were presumed to be good because the men were rated as on active duty three and a half to ten months after the wires were removed.

Screw suspension[6, 11, 56-59] is, as its name implies, a method of *suspending* the scapula from the clavicle by a vitallium lag screw (Fig. 3) until the torn coracoclavicular ligaments heal. It is *not* fixation.[60] This procedure accomplishes the effects of syndesmopexy and ligamentoplasty by a relatively simple and minor operation performed through a small incision under local anesthesia.

Certain points in technic are essential to success. The acromioclavicular joint must first be reduced. The hole in the clavicle should be somewhat larger than the screw shaft. The screw must be made to bite its own way into the coracoid, without previous drilling, and it should be set deeply enough firmly to grip both the upper and the lower cortices of the coracoid. Postoperative management includes immediate use of the extremity for all light activities, such as shaving and dressing. All lifting, pulling or pushing must be absolutely prohibited for eight weeks, since during this period the screw alone is depended upon for support.

In 1941 the first 4 cases in which this procedure was carried out were reported.[6] Later, the method was independently devised by Vere-Hodge[58] in England, where it was used during the recent war. He has done 7 cases with very satisfactory results at three weeks to four years after operation.[12] Dyer[56] has reported 4 cases with excellent results at two to six months. Stewart[57] discussed 9 patients op-

erated on successfully. My first 10 patients have now been followed personally for four months to seven and a half years (Fig. 4). In 8 the result is rated as excellent, with no deformity or pain, with a full range of active and passive motion and with normal strength. One patient obtained an excellent result of the acromioclavicular repair but has some limitation of abduction from a surgical-neck fracture of the humerus on the same side, subsequently incurred. It is interesting to note that, although the later injury was severe enough to fracture this patient's humerus, the acromioclavicular joint did not redislocate. In an early case in which complete reduction had not been obtained at the time of operation the thin screw that was then being used broke at a later date and redislocation occurred. This patient refused reoperation.

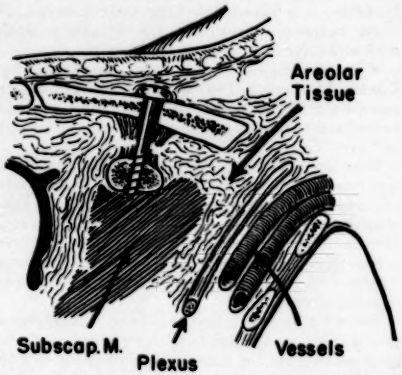

FIGURE 3. *Screw Suspension, which Maintains the Torn Ends of the Coracoclavicular Ligament in Apposition Until Healing Re-establishes Ligamentous Support.*

Motion at the acromioclavicular joint is preserved because the hole drilled in the clavicle is larger then the screw shaft.

An additional 8 cases operated upon by six other surgeons, with follow-up periods of one month to four years, were reported earlier this year.[11] Seven of these patients had excellent results, and there was 1 failure. The known end results, therefore, in 38 cases operated upon by ten different surgeons were: good in 36, with failure in 2.

Discussion

It must be admitted that satisfactory results are sometimes obtained by nonoperative treatment.[24, 26, 27, 35, 37, 39] However, externally applied restrictive dressings are uncomfortable to wear, they require constant supervision and adjustment, they involve a protracted disability, and in many cases operative intervention is eventually required. In my experience, certain nonoperative methods, such as adhesive strapping, Velpeau dressings and figure-of-eight bandaging, are utterly ineffective in maintaining reduction of a complete dislocation and should not be used.

Most experienced clinicians prefer some form of surgical operation in the treatment of this lesion. The specific procedure chosen will vary with the individual experience and prejudices of the surgeon. Excision of the outer portion of the clavicle and fusion of the acromioclavicular joint both seem to me unphysiologic and unnecessarily radical. After excision of the end of the clavicle most patients experience easy fatigue and weakness in the operated shoulder as compared with the normal, and there is a certain amount of displacement of the affected shoulder.[35] This is to be expected when the strut-like support of the clavicle is removed. Fusion of the acromioclavicular joint, by completely eliminating joint motion, necessarily interferes with full shoulder function, especially abduction, as has been proved experimentally.[5]

I consider it far better to preserve the acromioclavicular joint and to restore its function by one of the reparative methods described above. Skeletal traction is the least desirable of these, owing to the risk of infection. Syndesmopexy and ligamentoplasty are major operations. They require a general anesthetic, hospitalization for one or two weeks and a prolonged period of disability and rehabilitation. An additional objection to syndesmopexy is that wire or silk sutures tend to cut through living bone by pressure necrosis when subjected to constant strain over a period of time.

FIGURE 4. *Excellent Function More than Seven Years after Screw Suspension for Complete Right Acromioclavicular Dislocation.*

The screw is still in place.

One must face the fact that the majority of these injuries are treated by the general surgeon and that most surgeons will see only a few such cases during all their years of practice. Therefore, a technically

simpler operation is to be preferred, if its results are comparable to those of the more radical procedures.

There are certain disadvantages inherent in wire transfixion-fixation. The acromioclavicular joint is completely immobilized, with consequent limitation of motion, for eight weeks. Two operations are required, for the wires must be removed. Wires that have migrated from the shoulder have had to be removed from the neck and even from the lung.[51]

The method of screw suspension is free of these objections. Mobilization of the upper extremity is assured from the day of operation. In fact, most patients feel so well that it is difficult to keep them from overdoing. In only the exceptional case need the screw ever be removed. I know of no case in which a screw has migrated to another part of the body. The operation is physiologically sound; suspensive reinforcement is provided at the exact point where it is required anatomically and functionally—and without fixation. No important structures are endangered by the screw.

Summary

The various nonoperative and operative methods of treating complete acromioclavicular dislocation are reviewed, and their merits and faults discussed and their end results presented. Screw suspension appears to be the simplest, safest and surest procedure thus far devised for this disabling lesion.

44 Pondfield Road

References

1. Codman, E. A. *The Shoulder: Rupture of the supraspinatus tendons and other lesions in or about the subacromial bursa.* 513 pp. Boston: Thomas Todd Co., 1934.
2. *Human Anatomy: Including structure and development and practical considerations.* Edited by G. A. Piersol. Seventh edition. 2104 pp. Philadelphia: J. B. Lippincott Company, 1919.
3. Liberson, F. Role of coracoclavicular ligaments in affections of shoulder girdle. *Am. J. Surg.* 44:145-157, 1939.
4. Sandstrom, C. J., and Saltzman, A. Comparative study of clavicular ligaments of rat, rabbit, cat and dog. *Anat. Rec.* 89:23-32, 1944.
5. Inman, V. T., Saunders, J. B. deC. M., and Abbott, L. C. Observations on function of shoulder joint. *J. Bone & Joint Surg.* 26:1-30, 1944.
6. Bosworth, B. M. Acromioclavicular separation: new method of repair. *Surg., Gynec. & Obst.* 73:866-871, 1941.
7. Nutter, P. D. Coracoclavicular articulations. *J. Bone & Joint Surg.* 23:177-179, 1941.
8. Slocum, D. B. Coracoclavicular joint. *Northwest Med.* 40:16, 1941.
9. del Valle, D., Jr., and Giordano, A. Síndrome doloroso cérvico-braquial originado por articulación coracoclavicular: operacion; curación. *Rev. argent. norteam. cien. méd.* 1:687-693, 1943.
10. Soule, A. B., Jr. Ossification of coracoclavicular ligament following dislocation of acromioclavicular articulation. *Am. J. Roentgenol.* 56:607-615, 1946.
11. Bosworth, B. M. Acromioclavicular dislocation: end-results of screw suspension treatment. *Ann. Surg.* 127:98-111, 1948.
12. Vere-Hodge, N. Personal communication.
13. Murray, G. Fixation of dislocations of acromioclavicular joint and rupture of coracoclavicular ligaments. *Canad. M. A. J.* 43:270, 1940.
14. Rawlings, G. Acromioclavicular dislocations and fractures of clavicle: simple method of support. *Lancet* 2:789, 1939.
15. O'Malley, M. G. Common fractures and dislocations of clavicle and shoulder joint. *Practitioner* 144:579-588, 1940.
16. Palma, E. C. Esguince del hombro por lesión de los ligamentos córacoclaviculares. *Arch. urug. de med., cir. y especialid.* 16:497-506, 1940.
17. Parker, A. P. Fractures and dislocations of shoulder girdle and ribs. *S. Clin. North America* 20:1613-1631, 1940.
18. Mumford, E. B. Acromioclavicular dislocation: new operative treatment. *J. Bone & Joint Surg.* 23:799-802, 1941.
19. Thorndike, A., Jr., and Quigley, T. B. Injuries to acromioclavicular joint: plea for conservative treatment. *Am. J. Surg.* 58:250-261, 1942.
20. Vianna, A. Luxação acromio-clavicular. *Bahia med.* 13:119-121, 1942.
21. Giannestras, N. J. Method of immobilization of acute acromioclavicular separation. *J. Bone & Joint Surg.* 26:597-599, 1944.
22. Lord, C. D., and Coutts, J. W. Typical parachute injuries: study of those occurring in 250,000 jumps at parachute school. *J. A. M. A.* 125:1182-1187, 1944.
23. Usadel, G. Zur Behandlung der Luxatio claviculae supraacromialis. *Arch. f. klin. Chir.* 200:621-626, 1940.
24. Ehlert, H. Die Luxation im Acromio-Clavicular gelenk. *Zentralbl. f. Chir.* 66:1895-1898, 1939.
25. Goldberg, D. Acromioclavicular joint injuries: modified conservative form of treatment. *Am. J. Surg.* 71:529-531, 1946.
26. Anderson, R., and Burgess, E. Acromioclavicular dislocation: conservative method of treatment. *Northwest Med.* 38:40-44, 1939.
27. Howard, N. J. Acromioclavicular and sternoclavicular joint injuries. *Am. J. Surg.* 46:284-291, 1939.
28. Howard, N. J. Diagnosis and treatment of certain injuries of shoulder girdle. *S. Clin. North America* 22:1019-1073, 1942.
29. Gibbens, M. E. Appliance for conservative treatment of acromioclavicular dislocation. *J. Bone & Joint Surg.* 28:164, 1946.
30. do Amaral, A. C. Luxação acromio-clavicular: dispositivo of Ottolenghi-Lagomarsino. *Rev. med.-cir. do Brasil* 46:391-401, 1938.
31. Hart, V. L. Treatment of acute acromioclavicular dislocation. *J. Bone & Joint Surg.* 23:175, 1941.
32. Muscolo, D. Luxación acromioclavicular: dispositivo para su tratamiento y trabajo experimental. *Rev. ortop. y traumatol.* 11:69-78, 1941.
33. Roca, C. A. Luxaciones acromioclaviculares: sobre un aparato para su tratamiento. *Rev. san. mil., Buenos Aires* 40:804, 1941.
34. Wolin, I. Acute acromioclavicular dislocation: simple, effective method of conservative treatment. *J. Bone & Joint Surg.* 26:589-592, 1944.
35. Urist, M. R. Complete dislocations of acromioclavicular joint: nature of trauma, lesion and effective methods of treatment with analysis of forty-one cases. *J. Bone & Joint Surg.* 28:813-837, 1946.
36. Zanuso, F. Nuovo contributo alla cura della lussazione acromio-clavicolare. *Rassegna previd. sociale* 27:38-48, 1940.
37. Morrison, G. M. Cast treatment of acromioclavicular dislocations. *J. Bone & Joint Surg.* 30*A*:238, 1948.
38. Caldwell, G. A. *Treatment of Fractures.* 303 pp. New York: Paul B. Hoeber, Inc., 1943. P. 181.
39. Metz, A. R. Discussion of Thorndike and Quigley.[19]
40. Gurd, F. B. Treatment of complete dislocation of outer end of clavicle: hitherto undescribed operation. *Ann. Surg.* 113:1094-1098, 1941.
41. Caldwell, G. D. Treatment of complete permanent acromioclavicular dislocation by surgical arthrodesis. *J. Bone & Joint Surg.* 25:368-374, 1943.
42. Gioia, T. Tratamiento de las luxaciones supraacromiales de la clavicula. *Semana méd.* 1:57-61, 1938.
43. Zaragaza, J. Luxación acromio-clavicular completa. *Dia méd.* 10:578-580, 1938.
44. Campos, O. P. Acromioclavicular dislocation. *Am. J. Surg.* 43:287-291, 1939.
45. Appell, A. A. Acromio-clavicular dislocation. *Canad. M. A. J.* 43:23-25, 1940.
46. Vargas, L. Repair of complete acromioclavicular dislocation, utilizing short head of biceps. *J. Bone & Joint Surg.* 24:772, 1942.
47. Pontes, A. Luxação acromio-clavicular. *Brasil-med.* 58:279-281, 1944.
48. Birkett, A. N. Result of operative repair of severe acromio-clavicular dislocation. *Brit. J. Surg.* 32:103, 1944.
49. Adam, M. R. Un point de technique touchant les syndesmopexies coraco-claviculaires. *Rev. d'orthop.* 31:220-222, 1945.
50. Toumey, J. W., and Haggart, G. E. Surgery of shoulder joint. *S. Clin. North America* 22:883-897, 1942.
51. Bunnell, S. Fascial graft for dislocation of acromioclavicular joint. *Surg., Gynec. & Obst.* 46:563, 1928.
52. Gilje, L. E. Personal communication.
53. Cleveland, M. Personal communication.
54. Phemister, D. B. Treatment of dislocation of acromioclavicular joint by open reduction and threaded-wire fixation. *J. Bone & Joint Surg.* 26:166-168, 1942.
55. Bloom, E. A. Wire fixation in acromioclavicular dislocation. *J. Bone & Joint Surg.* 27:273-276, 1945.
56. Dyer, J. D. Acromioclavicular injuries. *Mississippi Doctor* 23:363-365, 1945.
57. Stewart, R. Acute acromio-clavicular joint dislocation: internal fixation of clavicle and coracoid process of scapula with vitallium screw. *Minnesota Med.* 29:357, 1946.
58. Vere-Hodge, N. Cited by Watson-Jones.[59]
59. Watson-Jones, R. *Fractures and Joint Injuries.* Third edition. 2 vol. 960 pp. Edinburgh: E. & S. Livingstone, Ltd., 1943. Vol. 2. P. 434.
60. Tyler, G. T., Jr. Acromioclavicular dislocation fixed by vitallium screw through joint. *Am. J. Surg.* 58:245, 1942.
61. Mazet, R., Jr. Migration of Kirschner wire from shoulder region into lungs: report of two cases. *J. Bone & Joint Surg.* 25:477-483, 1943.

NOCARDIOSIS

Pneumonia and Empyema due to *Nocardia Asteroides*

HERBERT F. HAGER, M.D.,* ANTHONY V. MIGLIACCIO, M.D.,† AND RAYMOND M. YOUNG, PH.D.‡

PROVIDENCE, RHODE ISLAND

IN 1888 Nocard[1] described an acid-fast sporothrix, *Actinomyces farcinicus*, as the cause of *farcies du boeuf*, or bovine farcy. Eppinger,[2] in 1891, reported an aerobic, gram-positive, acid-fast actinomyces as the etiologic agent in a man dying with cerebral abscesses and meningitis. Since then the species of actinomycetes having acid-fast properties has been known as *Streptothrix eppingeri, S. asteroides, Oospora asteroides, Actinomyces asteroides, Nocardia gypsoides* and more recently *N. asteroides*.

The literature on infections caused by this organism is not voluminous and indicates that cases are not common. The diagnosis in the great majority of cases was made only at autopsy or in the late stages of the illness. Furthermore, in the 37 cases reported, only 6 patients are known with any certainty to have survived. One of these was a case of Madura foot treated by amputation of the extremity.

Henrici and Gardner,[3] in 1921, collected 26 cases of acid-fast actinomyces and added a case. Most of these cases apparently were of pulmonary origin. In the case reported the patient was treated with an antigen made from the cultures. The final results of this treatment are unknown. Goldsworthy,[4] in 1937, and Kessel and Goolden,[5] in 1938, reported fatal cases. Benbow, Smith and Grimson,[6] in 1944, described 2 cases in which surgical drainage, vitamin therapy, roentgen-ray therapy and sulfonamide therapy were used. These were the first reported cases in which the patients are known to have recovered except for the one treated by amputation. In 1945 Binford and Lane[7] discussed a case diagnosed at autopsy. Kirby and McNaught,[8] in 1946, added 2 more fatal cases. In 1946 Shaw, Holt and Ray[9] reported a case successfully treated with penicillin, thymol, potassium iodide, sulfadiazine, and surgical drainage of an empyema cavity. In the same year Calero[10] described a twelve-year-old white girl who was considered cured after therapy with sulfonamides and penicillin, but who at the time of dismissal still had an elevated sedimentation rate.

Glover et al.,[11] in 1948, summarized the literature and reported in detail the case of a twenty-six-year-old physician in whom the diagnosis of nocardiosis was established more than two years after the onset of his illness. He was considered successfully treated by sulfadiazine after penicillin and streptomycin had failed. The authors believed that if the case of Madura foot cured by amputation and the case treated with antigen in which the final outcome was not known were excluded, only 5 of the 37 known cases could be considered clear-cut examples of recovery. They attributed the success in these cases to the administration of sulfadiazine. On the basis of their studies and those of Drake,[12] they doubted whether penicillin or streptomycin was effective in the treatment of this disease.

The first case of *N. asteroides* infection reported below failed to respond to sulfadiazine, penicillin or streptomycin until surgical drainage of an empyema cavity was instituted and until these antibiotics were used in combination and in large doses. This combined therapy apparently resulted in complete recovery, since the patient was free of symptoms and signs twelve months after discontinuance of all therapy. The case is of further interest in that the diagnosis was established early in the course of the illness.

A second case of pulmonary infection presumably due to Nocardia asteroides has recently been observed. A detailed report of the case is not presented, but results of the sensitivity tests of the organism to sulfadiazine, penicillin, streptomycin and aureomycin are reported.

CASE REPORT

CASE 1. O. M., a 16-year-old schoolgirl, had been well and active during the year prior to her present illness except for an upper respiratory infection, which had occurred 2 months earlier and which had been diagnosed as influenza. On December 24, 1947, she felt feverish and weak, and had pain in the right lower portion of the chest anteriorly. On the following day, the temperature was 100.6°F., and there was splinting of the respiratory muscles on the right side. Posteriorly, the breath sounds were bronchovesicular and diminished, but no rales could be heard. There was a soft systolic murmur at the fourth left interspace. The patient had two episodes of spontaneous epistaxis. Sulfadiazine therapy with equal amounts of sodium bicarbonate was given. On December 28 the temperature had risen to 102.8°F., and the physical signs suggested further extension of the pulmonary lesion, together with findings of free fluid in the right pleural space. There was a cough, which persisted, but sputum was raised on only one occasion. The patient was admitted to the Rhode Island Hospital, where she remained for the duration of her acute illness.

A roentgenogram of the thorax (Fig. 1) on admission to the hospital revealed the heart to be slightly enlarged, but with a normal contour. The left-lung field and diaphragm were normal. The right-lung field showed an area of diffuse density in the lower half through which the diaphragm could be seen faintly. In the lateral half of the right upper portion of the chest there was a large, localized area of density believed to represent an encapsulated collection of fluid in the pleural space.

*Physician, Outpatient Department, Rhode Island Hospital and Charles V. Chapin Hospital.

†Associate surgeon, Rhode Island Hospital; surgeon, Rhode Island State Infirmary; member, consulting staff, Charles V. Chapin Hospital.

‡Research bacteriologist, Institute of Pathology, Rhode Island Hospital.

The urine was normal. Examination of the blood showed a red-cell count of 3,500,000, with a hemoglobin of 11.8 gm., and a white-cell count of 13,850, with 77 per cent neutrophils, 11 per cent lymphocytes and 12 per cent monocytes. The blood urea nitrogen was 9 gm. per 100 cc. A blood culture on December 28, 1947, and numerous subsequent cultures were sterile. A sputum culture revealed *Streptococcus viridans* to be the predominating organism. No acid-fast organisms were seen.

In summary, the only abnormal physical findings were those pertaining to the pulmonary lesion and the general febrile reaction. The patient clinically did not appear as ill as would be expected in a pneumococcal pneumonia, and another etiologic agent was suspected.

The patient was given 100,000 units of crystalline penicillin intramuscularly on admission, and 50,000 units every 3 hours. On the 2nd hospital day the temperature was normal, but subsequently it rose irregularly each day for the next few weeks. On December 30 aspiration of the pleural space was attempted posteriorly and anteriorly, but only 2 cc. of sterile, bloody fluid was obtained. On January 6, 1948, a second aspiration high in the axilla in the third interspace resulted in 20 cc. of sterile serosanguineous fluid. After each aspiration, 100,000 units of penicillin was instilled. A roentgenogram of the chest on January 6 showed considerable clearing of the density in the lower-right-lung field, and the encapsulated fluid in the right upper portion of the chest was much smaller in amount. A small quantity of fluid was present in the right costophrenic sulcus.

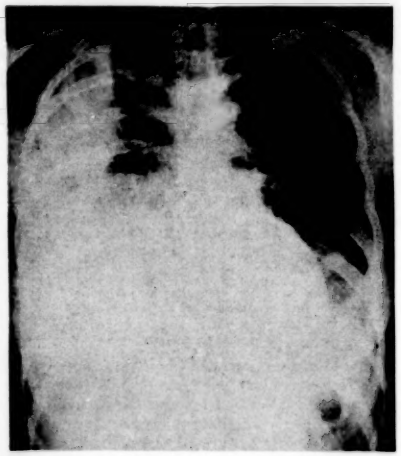

FIGURE 1. *Roentgenogram of the Chest Taken on Admission in Case 1.*

On January 8, the penicillin was discontinued despite the persistence of slight elevations of the temperature to 99.8°F. daily. Roentgenograms continued to show clearing of the pneumonic process and lessening of the free fluid. On January 15 the temperature spiked irregularly to higher levels reaching 101°F. daily, and penicillin therapy was again instituted. This elevation of temperature was interpreted as being due to the formation of a loculated empyema. The right leaf of the diaphragm was elevated, and the mediastinum was shifted slightly to the left. Penicillin was omitted 4 days later after no improvement, and intramuscular injections of streptomycin, totaling 1.8 gm. a day, were instituted. The patient continued to have a dry, hacking cough, but her general condition was good despite the prolonged fever. At this time the signs in the axilla had cleared, but there continued to be dullness to percussion and diminished breath sounds posteriorly. On January 20 the temperature rose to 104°F., and roentgenograms (Fig. 2) showed a new dense shadow in the right lower portion of the chest posteriorly consistent with encapsulated fluid. There was a smaller loculation of fluid in the upper peripheral portion of the chest. On January 21 a diagnostic thoracentesis was performed, and free-flowing, foul-smelling, pea-green fluid was withdrawn. Smears

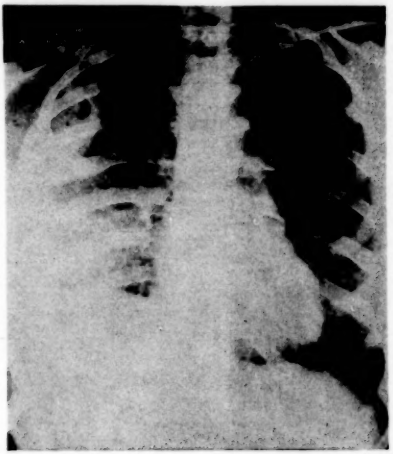

FIGURE 2. *Roentgenogram of the Chest Taken on January 21, 1948, in Case 1.*

and cultures of this fluid revealed a gram-positive, acid-fast, branching, aerobic organism identified as *N. asteroides*, and gram-negative anaerobic fusiform bacteria.

On the same day a rib resection and open drainage of the empyema cavity were performed, and a large rubber tube was left in place. The cavity was narrow and lined by dense fibrous tissue, which obliterated the surrounding pleural space. It had been entered at the lowest point and dependent drainage was obtained. Antibiotic therapy was increased so that 500 mg. of streptomycin and 500,000 units of penicillin were given intramuscularly every 6 hours. Sulfadiazine, 6 gm. a day, was begun, the dosage later being increased to 9 gm. a day. Sodium citrate was used to alkalinize the urine. Potassium iodide was given by mouth; 500 cc. of whole blood was given on two occasions.

Sensitivity tests revealed this strain of *N. asteroides* to be inhibited by concentrations of between 0.004 and 0.008 units of penicillin per cubic centimeter, 0.03 and 0.06 units of streptomycin per cubic centimeter, and 0.62 and 1.24 mg. of sulfadiazine per 100 cc. The blood levels of sulfadiazine ranged from 7.0 to 17.3 mg. per 100 cc. of free sulfadiazine and from 7.3 to 18.8 mg. per 100 cc. of total sulfadiazine. No hematuria or toxic effects from the sulfadiazine or penicillin were noted. On the 27th day of streptomycin therapy, the patient complained of slight dizziness, and when she walked with her eyes closed she staggered considerably. This staggering when visual control of balance is eliminated has persisted ever since, although the Romberg test is nega-

tive and there is no disturbance of gait with the eyes open. No loss in auditory sensitivity has been detected. Streptomycin was discontinued immediately on the appearance of toxic signs after a total of 56.7 gm. had been given. On February 25 penicillin, sulfadiazine and potassium iodide were omitted, and no further antibiotic therapy was administered. The patient received a total of 76,600,000 units of penicillin intramuscularly, 10,700,000 units of penicillin intrapleurally and 288 gm. of sulfadiazine orally.

After surgical drainage, the temperature fell to normal and remained so. The operative wound remained clean, and the cavity closed rapidly with little drainage; 500,000 units of penicillin was instilled daily as long as the cavity was open. The tube was removed 21 days after the operation. Iron therapy, in addition to the transfusions, was given for the mild hypochromic anemia. The white-cell count at the height of the illness reached 15,000, with 80 per cent neutrophils. After administration of streptomycin the eosinophils rose from 0 to 42 per cent, whereas the white-cell count returned to a normal of 8050. The sedimentation rate remained elevated until 2 weeks after discharge from the hospital but has subsequently been normal. The cultures of the fluid from the empyema cavity became sterile immediately after surgical drainage of the cavity, but acid-fast, branching rods were seen in the fresh smears 9 days later. The roentgenograms of the thorax taken since discharge have shown complete clearing of the pulmonary lesion (Fig. 3).

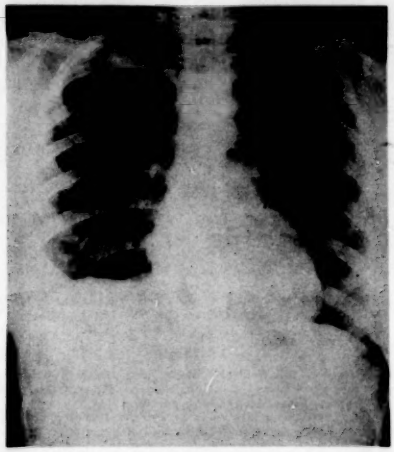

FIGURE 3. *Final Roentgenogram of the Chest Taken since Discharge in Case 1.*

CASE 2. E. H., a 64-year-old woman, entered the hospital with a history of chronic cough of 3 years' duration, attacks of respiratory distress diagnosed as bronchial asthma and episodes of fever associated with pulmonary difficulty. An x-ray film of the thorax revealed (Fig. 4) bilateral apical pulmonary lesions. The film was interpreted as showing a moderate amount of fibrotic streaking involving the entire apical portion of the right upper lobe and a number of discrete, calcific deposits in the apex of the left upper lobe. Small calcified nodules were present in the upper portion of the right hilus. No definite cavitation could be made out. The cough was productive of thick, greenish sputum, which was consistently negative for tubercle bacilli but from which *N. asteroides* was isolated as the predominating organism on several occasions. The patient was afebrile during a short period of observation at the Rhode Island Hospital.

This strain of *N. asteroides* was found to be inhibited by concentrations of between 0.015 and 0.03 units of penicillin, 0.12 and 0.24 units of streptomycin and 0.5 and 1.0 unit of aureomycin per cubic centimeter, but was not inhibited by 60 milligrams of sulfadiazine per 100 cc. of medium.

FIGURE 4. *Roentgenogram of the Chest in Case 2.*

BACTERIOLOGY

The Nocardia asteroides organism appears in Ziehl–Neelsen stains of smears made from fresh purulent material as short branching or single rods that are definitely acid fast; however, smears made from the primary culture of the clinical material show partially and irregularly acid-fast elements, and in addition to branching and rod forms there are fine mycelial filaments, some of which fragment into coccoid conidia (Fig. 5). With continued transfer on artificial mediums, the organism tends to lose the acid-fast property. This is particularly true when acid alcohol of the Ziehl–Neelsen technic is used to decolorize; however, by the use of a weak solution of sulfuric acid to decolorize, acid-fast elements may be observed in spite of several transfers on artificial mediums. Different strains of the organism show varying degrees of acid fastness, and the cells of old cultures tend to show more irregularity in this regard.

The organisms are gram positive, but, as is true with most gram-positive species, they tend to lose

the property upon aging so that old cultures become gram-negative.

Nocardia asteroides grows well on routine blood-agar and Sabouraud's mediums under aerobic conditions at 37°C. Colonies appear rapidly, within twenty-four to forty-eight hours, under these conditions and show a dry wrinkled growth, which adheres to the surface of the medium (Fig. 6). The surface of the colony develops a chalky white appearance, whereas the portion in contact with the medium shows varying degrees of pigmentation, tan to deep orange. In poured plates the organism grows in small star-like colonies, which suggested the species term "asteroides." The pigmentation and morphologic appearance of the colonies vary with the mediums used and the age of the culture; hence the duplication of names appearing in the literature for this species. The usual sodium hydroxide method for concentration of sputum for tuberculosis destroys *N. asteroides* so that animal inoculations and cultures show no growth of the nocardia organism. The weak or semi-acid-fast property may not be noted when routine decolorization of the Ziehl–Neelsen stain is done and the

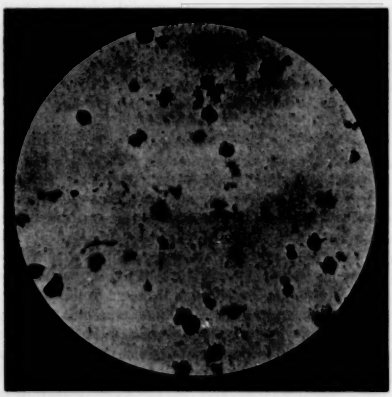

FIGURE 5. *Primary Culture of Smear, Showing* Nocardia asteroides *(Ziehl–Neelsen Stain).*

acid alcohol is allowed to remain too long on the smear. These facts may account for the recognition of so few cases.

The tissue lesions caused by *N. asteroides* differ from those in actinomycosis in that clubbed forms are not produced; nor are nodules or "sulfur granules" formed. The typical lesion is an abscess whose center is composed of necrotic material and leukocytes. Surrounding this material there is an area of dense cellular fibrous tissue, fibrin, neutrophils, lymphocytes, plasma cells and macrophages with branching organisms scattered throughout the tissues.[5] The lesions differ from the tuberculous process in that there is no caseation, no epithelioid tubercles and no giant cells. The dispersed mycelia may not show up with the usual hematoxylin and eosin stains but can be demonstrated readily with Gram's stain.

Acid-fast actinomyces occur naturally in the soil. Gordon and Hagan[12] find no features that would

FIGURE 6. *Blood-Agar Plate, Showing Colonies of* Nocardia asteroides.

serve to distinguish these soil forms from the pathogenic stains. A similar organism was isolated from a normal throat in 1 case.[13] Rabbits, guinea pigs and other laboratory animals are fairly resistant to infection with strains that cause disease in human beings.

The development of an allergic reaction can be demonstrated in animals after intratesticular injection of an oil suspension of the live organisms and the use of cutaneous tests. Protein extracts of the organisms cause a swollen area with central necrosis. The allergens are thermolabile and appear to be specific with no cross reactions with tuberculin.[14] By using 0.5 cc. of a crude extract of unheated, defatted organisms passed through a Berkefeld filter candle, Glover et al.[11] demonstrated positive intracutaneous reactions in twenty-four to forty-eight hours in their patient.

DISEASE IN MAN

The great majority of cases reported indicate that the infection usually begins in the lung, or

that a pulmonary metastasis from some other focus occurs early in the disease. The pulmonary lesion may remain quiescent or asymptomatic for some time, since the metastatic blood-borne secondary abscesses are frequently the ones to be noted first or to cause symptoms. The pulmonary lesions frequently extend to the pleuras, giving rise to an empyema that may form chronic draining sinuses to the chest wall. Of the metastatic lesions, brain abscesses have frequently been noted, and have most often been the lesion causing death. In some cases positive blood cultures have been obtained.[8] Subcutaneous abscesses are frequently encountered, and the skin may be involved. Some of the cases examined at autopsy have revealed multiple miliary abscesses in many of the organs of the body, such as the brain, liver, spleen, kidneys, adrenal glands, intestinal wall, lymph nodes and muscles.

The most frequently encountered symptoms were anorexia, weight loss, weakness and a chronic cough, which as the disease progressed became productive of foul, greenish, purulent sputum. Hemoptysis was rarely encountered, and cavitation was not usual. In some cases, pulmonary signs and symptoms were completely lacking, and the patients came to medical attention because of the neurologic signs of an intracranial abscess or because of abscesses or draining sinuses. The disease is most easily confused with tuberculosis, and when the illness is localized to a chronic pulmonary infection the true diagnosis may not be established for many months. Two cases of peritonitis have followed operations on the esophagus. The patients in the cases reported have been of all ages from an infant twenty-eight days old to elderly people. The division between the sexes has been approximately equal. The pulmonary lesions may occur in any lobe, and there is often early involvement of the peribronchial lymph nodes. A hypochromic anemia was frequently observed to develop as the infection persisted. Some of the patients died within two weeks of the onset of symptoms, whereas in others the infection was active for at least three years. The average duration of the fatal cases was six months. In every case the diagnosis must be made by bacteriologic study, but it should be suspected in all cases of pulmonary lesions in which the tubercle bacillus cannot be demonstrated or when miliary abscesses are encountered.

Treatment

The literature is of little value as a guide to treatment. Prior to the use of the antibiotics, the iodides and thymol were the usual agents and no patients survived. The authors of the reports of the few successfully treated cases are not in full agreement concerning the procedure or drug of choice. When possible the sensitivity of the organism at hand should be tested, and the antibiotics that are effective in inhibiting it should be utilized either alone or in combination. Of the sulfonamides, sulfadiazine or sulfamerazine seems to be the most active and the least likely to cause toxic reactions. When these drugs are utilized the urine should be alkalinized with sodium bicarbonate or sodium citrate. Penicillin in large doses — or by the utilization of some medication such as caronamide to achieve a sufficiently high blood level to inhibit the organism — seems to be the safest drug available. In the case reported by Glover and his associates,[11] the organism was not inhibited by 100 units of penicillin per cubic centimeter of medium. Streptomycin in sufficient concentration inhibits the organism in vitro, but the possible toxic effects on the eighth cranial nerve, with permanent impairment of hearing and the equilibrium mechanism, must be fully appreciated, and the danger accepted. This toxicity, it is now realized, may occur early in therapy and even with small or moderate dosage. Whether dihydrostreptomycin hydrochloride or aureomycin is equally effective in vivo against this organism is not known. The second strain isolated by us was inhibited readily by aureomycin in vitro. It is sound surgical practice to remove by surgical drainage or by aspiration any collections of purulent material. Instillation for local action of the antibiotics is believed to be helpful. In any event, it is necessary to observe the patient carefully for several years for a recurrence, for in 1 case[9] a reactivation of the infection occurred eleven months after all symptoms and signs had abated.

Summary

The pertinent literature in infections with the acid-fast aerobic actinomycetes *Nocardia asteroides* is reviewed. The characteristics of the organism and of the infection in man are given in brief. A case of pulmonary infection complicated by empyema in a sixteen-year-old schoolgirl is presented. This case was apparently successfully treated by surgical drainage and combined therapy with sulfadiazine, penicillin and streptomycin.

A second strain of *N. asteroides* was isolated from the sputum of a sixty-four-year-old woman with bilateral apical pulmonary lesions. This organism by in vitro tests was found to be inhibited by penicillin, streptomycin and aureomycin, but not by sulfadiazine with levels that usually can be attained clinically when adequate dosages of these antibiotics are administered.

Failure to recognize *N. asteroides* as the etiologic agent in certain infections may account for the scarcity of cases reported. Such failure may be due to the way in which routine specimens of sputum are prepared for inoculation or examination. It is stressed that large doses of the antibiotics to which the organism is sensitive may have to be given and that it may be necessary to administer combinations of two or more in order to obtain prompt inhibition of the organism. Surgical drainage or as-

piration of loculated collections of pus is believed advisable for early healing. Observation for a period of years after apparent arrest of the condition is advisable.

References

1. Nocard, E. Note sur la maladie des boeufs de la Guadaloupe connue sous le nom de farcin. *Ann. de l'Inst. Pasteur, Paris* **2**:293-302, 1888.
2. Eppinger, H. L. Über eine neue, pathogene Cladothrix und eine durch sie hervorgerufene Pseudotuberkulosis. *Beitr. z. path. Anat. u. z. allg. Path.* **9**:287-328, 1891.
3. Henrici, A. T., and Gardner, E. L. Acidfast actinomyces: with report of case from which new species was isolated. *J. Infect. Dis.* **28**:232-248, 1921.
4. Goldsworthy, N. E. Pulmonary actinomycosis caused by acid-fast species of actinomyces. *J. Path. & Bact.* **45**:17-27, 1937.
5. Kessel, J. F., and Goolden, E. B. Comparison of strains of actinomyces recovered from human lesions. *Am. J. Trop. Med.* **18**:689-701, 1938.
6. Benbow, E. P., Jr., Smith, D. T., and Grimson, K. S. Sulfonamide therapy in actinomyces: two cases caused by aerobic partially acid-fast actinomyces. *Am. Rev. Tuberc.* **49**:395-407, 1944.
7. Binford, C. H., and Lane, J. D. Actinomycosis due to *Nocardia Asteroides*: report of case. *Am. J. Clin. Path.* **15**:17-23, 1945.
8. Kirby, W. M. M., and McNaught, J. B. Actinomycosis due to *Nocardia* asteroides: report of two cases. *Arch. Int. Med.* **78**:578-591, 1946.
9. Shaw, F. W., Holt, R. A., and Ray, E. S. Pulmonary actinomycosis due to *Actinomyces asteroides*. *Virginia M. Monthly* **73**:362-368, 1946.
10. Calero, C. Pulmonary actinomycosis (report of first case observed in Isthmus of Panama). *Dis. of Chest* **12**:402-408, 1946.
11. Glover, R. P., Herrell, W. E., Heilman, F. R., and Pfuetze, K. H. Nocardiosis: Nocardia asteroides infection simulating pulmonary tuberculosis. *J. A. M. A.* **136**:172-175, 1948.
12. Drake, C. H. Action of penicillin on several genera of Actinomycetales. *J. Bact.* **51**:199-203, 1946.
13. Gordon, R. E., and Hagan, W. A. Study of some acid-fast actinomycetes from soil with special reference to pathogenicity for animals. *J. Infect. Dis.* **59**:200-206, 1936.
14. Drake, C. H., and Henrici, A. T. Nocardia asteroides: its pathogenicity and allergic properties. *Am. Rev. Tuberc.* **48**:184-198, 1943.

Additional References

Conant, N. F., Martin, D. S., Smith, D. T., Baker, R. D., and Callaway, J. L. *Manual of Clinical Mycology*. 348 pp. Philadelphia: W. B. Saunders Co., 1944. Pp. 1-25.

Gammel, J. A. Actinomycosis without granules. *Arch. Dermat. & Syph.* **39**:287-297, 1934.

Guy, W. H., and Helmbold, T. R. Nocardiosis cutis gangrenosa. *Arch. Dermat. & Syph.* **27**:224-231, 1933.

ORTHOXINE IN BRONCHIAL ASTHMA*
A Clinical Evaluation

IRVING W. SCHILLER, M.D.,† FRANCIS C. LOWELL, M.D.,‡ WILLIAM FRANKLIN, M.D.,§ AND CLARENCE DENTON, M.D.¶

BOSTON

SINCE the elucidation by Chen and Schmidt[1] (1923) of the chemical structure and the pharmacologic effects of ephedrine, this drug has ranked with epinephrine as one of the most valuable medications for the treatment of bronchial asthma. Although less active as a bronchodilator than epinephrine, ephedrine is effective, and its action is prolonged. However, undesirable effects such as nervousness, tremulousness, sleeplessness, vertigo, sweating, anorexia, nausea and palpitation often interfere with the use of the drug or require the additional administration of sedatives. In the last few years, therefore, attempts have been made to produce sympathomimetic compounds with less effect on the cardiovascular and central nervous systems. One of these, orthoxine,|| orthomethoxy-b-phenylisopropyl methylamine hydrochloride (Fig. 1), appears to have certain advantages over ephedrine.

In animal experiments orthoxine was found to be more effective than ephedrine in relieving bronchial spasm induced by histamine, pilocarpine and acetylcholine.[2, 3] It caused practically no pressor response and less stimulation of the central nervous system than ephedrine.[4] In man, orthoxine has furnished protection against asthma-like attacks induced with histamine or methacholine.[5, 6]

Materials and Methods

Fifty patients with bronchial asthma, about equally distributed between the sexes and ranging in age from four to sixty-three years (the majority being adults), served as subjects for this study. The perennial type of asthma predominated. Some patients were receiving treatment with specific allergenic extracts, and many of them had been instructed to eliminate offending allergens. All subjects were having mild to severe asthma at the time treatment with orthoxine was started, and they were observed for a period of weeks to several months. The dose varied from 50 mg. in children to

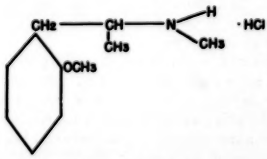

FIGURE 1. *Chemical Structure of Orthoxine.*

*From the Allergy Clinic, Robert Dawson Evans Memorial, Massachusetts Memorial Hospitals, and the Department of Medicine, Boston University School of Medicine.

†Instructor in medicine, Boston University School of Medicine; assistant physician, Allergy Clinic, Robert Dawson Evans Memorial, Massachusetts Memorial Hospitals.

‡Associate professor of medicine, Boston University School of Medicine; member of staff and physician-in-charge of Allergy Clinic, Robert Dawson Evans Memorial, Massachusetts Memorial Hospitals.

§Assistant in medicine, Boston University School of Medicine; assistant resident, Robert Dawson Evans Memorial, Massachusetts Memorial Hospitals.

¶Assistant in medicine, Boston University School of Medicine; research fellow, Robert Dawson Evans Memorial, Massachusetts Memorial Hospitals.

||Kindly supplied by the Upjohn Company, Kalamazoo, Michigan.

100 or 200 mg. in adults, given every four hours as needed. Control studies with placebos were used in some cases, and no benefit was observed. Relief of symptoms, when it occurred, was evident in twenty to thirty minutes. The results were classified as follows: excellent, if complete relief of symptoms occurred for several hours; fair, if relief was 50 per cent or more and lasted two or more hours; and unsatisfactory, if the relief was less than 50 per cent or if the duration of activity was short.

Results

As shown in Table 1, 18 (36 per cent) patients had excellent relief, 17 (34 per cent) obtained fair relief, and the remaining 15 (30 per cent) had unsatisfactory results. On the basis of the degree of asthma, patients with mild asthma fared best, followed by those with cases of moderate severity. Those with severe asthma obtained the least relief.

Table 1. *Therapeutic Response to Orthoxine.*

Degree of Asthma	No. of Cases	Excellent Relief	Fair Relief	Unsatisfactory Relief
		no. of cases	no. of cases	no. of cases
Mild	14	7	6	1
Moderate	21	10	4	7
Severe	15	1	7	7
Totals	50	18	17	15

Prior to the administration of orthoxine 28 patients had been taking ephedrine in one form or another or, having previously taken orthoxine, had substituted ephedrine. In this way we were able to gather some impression of the relative value of the two drugs, taking into account the degree of relief as well as the intensity of side reactions, discussed in detail below. Ten patients preferred orthoxine to ephedrine. In 2 there was no advantage in one drug over the other, whereas the remaining 16 preferred ephedrine to orthoxine.

In 4 patients, substitution of orthoxine for ephedrine was advantageous. Marked side effects with ephedrine developed in 3, and 1 of these had hypertension. In this patient and in a fourth, who had a recent coronary infarct, it was believed that ephedrine, because of its pressor effects, should not be given. All 4 of these patients tolerated orthoxine well and obtained excellent relief.

Observations were made in asthmatic subjects to determine the degree to which orthoxine could protect against asthma-like attacks and a fall in vital capacity following the inhalation of aerosolized allergenic extracts.[7-9] Three patients, all of whom had been tested in this manner and had had significant pulmonary reactions following inhalations of nebulized extracts (5 per cent birch pollen in 2 cases and 0.25 per cent Endo house dust in the remaining one) were chosen for this study. In brief, the patients came to the laboratory when free of asthma and in a fasting state. Three or four control vital capacities were recorded, after which 200 mg. of orthoxine was given by mouth. At the end of an hour the subjects were again tested with the nebulized extracts that had previously caused significant reductions in vital capacity. In no case did orthoxine protect the patients, the pulmonary response being almost identical with that experienced without the drug. Although this technic has been valuable in assaying drugs given parenterally or by inhalation,[8-10] administration of drugs by mouth has not given clear inhibition of asthma-like attacks induced with aerosolized allergenic extracts. This may be due to the lack of refinement of the method or to the relatively heavy exposure of the inhaled extract, which may mask slight or moderate activity of the drug. The lack of protection by orthoxine is of doubtful significance and is in contrast to the reported efficacy of this agent given by mouth in affording some degree of protection or relief in asthma-like attacks induced with histamine or methacholine given parenterally.[6]

Side Effects

Of the 50 subjects with asthma, 43 (86 per cent) were completely free from unpleasant side reactions. Of the remaining 7 (14 per cent), 4 had gastric disturbances as follows: questionable nausea in 2, nausea in 1, and nausea and vomiting in 1. The last patient was an eleven-year-old boy in whom the same symptoms likewise developed after the taking of ephedrine. Of the other 3 cases, 1 patient had menstrual-like cramps; 1 reported dizziness and sleeplessness, and 1 excessive perspiration. Four of these 7 patients with side reactions obtained little or no relief from orthoxine, so that the drug was discontinued. The remaining 3 had excellent or fair relief of asthma upon decrease in the dose of the drug to 50 mg., or, as in 1 case, when the drug had been withheld for a few days and was again given.

Discussion

The difficulty of judging the effectiveness of an oral preparation for use in bronchial asthma is recognized. Patients have a tendency to overestimate the benefits of any new drug when it is first used. Nevertheless, we believe that our impression of orthoxine is fairly well founded.

The response of 27 out of 35 patients with mild or moderate asthma was excellent or fair with orthoxine, which compares favorably with other well known oral sympathomimetic agents. Similar results with orthoxine were recently reported by Wittich.[11] However, the majority of our patients in whom comparison was possible, preferred ephedrine to orthoxine. In the 15 patients with severe asthma, the drug was relatively ineffective. In most cases, these patients obtained relief with other medications such as epinephrine, isuprel and aminophyllin. Our experience is not entirely in accord with the findings of

Curry, Fuchs and Leard,[6] who, in their clinical studies on 21 asthmatic subjects, observed orthoxine, in doses of 200 mg., to be comparable to ephedrine in 30-mg. doses. This discrepancy may be accounted for, in part, by the fact that we often used smaller doses of orthoxine and usually gave ephedrine with a barbiturate.

We are aware that results similar to those obtained with orthoxine might have been obtained with other preparations for asthma. However, the figures cited in Table 1 do not indicate the true value of a preparation such as orthoxine because they leave out of account reactions of individual patients. For instance, more patients may obtain relief from asthma with ephedrine than with orthoxine, as in the cases discussed above but in certain patients who may be unable to tolerate ephedrine, orthoxine may give relief and may be well tolerated. We believe, therefore, that orthoxine is a valuable addition to the list of agents available for the treatment of asthma.

Summary

Fifty patients with bronchial asthma were treated with orthoxine-orthomethoxy-b-phenylisopropyl methylamine hydrochloride. The drug is an effective oral sympathomimetic agent especially applicable to the milder cases of asthma.

Although it did not appear to be quite as effective as ephedrine, orthoxine had the advantage of causing less disturbance of the cardiovascular and central nervous systems. It is concluded that orthoxine is a distinct contribution to the management of bronchial asthma.

65 East Newton Street

References

1. Chen, K. K., and Schmidt, C. F. Action of ephedrine, active principle of Chinese drug Ma Huang. *J. Pharmacol. & Exper. Therap.* **24**: 339–357, 1924.
2. Woodruff, E. H. Phenethylamines. IV. Dimethoxy and dihydroxy-phenyl-n-propylamines (β-methyl-β phenethylamines). *J. Am. Chem. Soc.* **64**:2859–2862, 1942.
3. Graham, B. E., and Kuizenga, M. H. Pharmacological study of ortho-methoxy-beta-phenyl-isopropyl methylamine hydrochloride, and thirteen related methoxy analogues. *J. Pharmacol. & Exper. Therap.* **94**:150–166, 1948.
4. Burbidge, E. L. Personal communication.
5. Curry, J. J. Objective method for evaluating anti-asthmatic effect of several sympathomimetic amines in man. *J. Clin. Investigation* **26**:1178, 1947.
6. Curry, J. J., Fuchs, J. F., and Leard, S. E. Clinical and experimental studies with orthoxine in treatment of bronchial asthma. Presented at the annual meeting of the American Academy of Allergy, Atlantic City, New Jersey, December 6, 1948.
7. Lowell, F. C., and Schiller, I. W. Reduction in vital capacity of asthmatic subjects following exposure to aerosolized pollen extracts. *Science* **105**:317, 1947.
8. Schiller, I. W., and Lowell, F. C. Effect of drugs in modifying response of asthmatic subjects to inhalation of pollen extracts as determined by vital capacity measurements. *Ann. Allergy* **5**:564–566, 1947.
9. Lowell, F. C., and Schiller, I. W. Measurement of changes in vital capacity as means of detecting pulmonary reactions to inhaled aerosolized allergenic extracts in asthmatic supjects. *J. Allergy* **19**:100–107, 1948.
10. Lowell, F. C., Curry, J. J., and Schiller, I. W. Clinical and experimental study of isuprel in spontaneous and induced asthma. *New Eng. J. Med.* **240**:45–51, 1949.
11. Wittich, F. W. Clinical evaluation of orthoxine in treatment of allergic diseases. *Ann. Allergy* **6**:664–666, 1948.

CLINICAL OBSERVATIONS CONCERNING SCHIZOPHRENIC PATIENTS TREATED BY PREFRONTAL LEUKOTOMY*

Jay L. Hoffman, M.D.†

BEDFORD, MASSACHUSETTS

IT IS my purpose here to consider the clinical results of leukotomy in 42 patients treated by psychosurgery‡ at a Veterans Administration hospital during a two-year period — 1947 and 1948. To prepare for this I have reviewed the clinical records of these 42 patients and, within the past two weeks, have examined those who remained in the hospital. I have also gone over the social-service reports of the patients who have left the hospital and, in a few cases, have interviewed the relatives myself.

I am less concerned in this report with statistics than I am with the qualitative results following leukotomy. Therefore, the only figures that I will give are as follows: of the 42 patients operated on 4 (9 per cent) are now dead§; 14 (33 per cent) are out of the hospital — either discharged or on extended trial visit; 16 (38 per cent) are still in the hospital, although so far as behavior is concerned they could live at home equally well; and 8 (19 per cent) are still in the hospital and require hospital care because of continuing episodic disturbed behavior.

The evaluation of the results after prefrontal leukotomy will be greatly influenced by the frame of reference one uses. If the condition of the patient is compared with his condition prior to the onset of his psychosis, all the results must be considered failures, for the adjustment of none of the patients — when viewed with true objectivity — compares favorably with the prepsychotic status. If the clinical status after leukotomy is compared with the condition of the patient during the period of his psychosis, practically all the patients, who have survived will be found to show successful results. From the quantitative viewpoint none of the patients, after

*Published with the permission of the Chief Medical Director, Department of Medicine and Surgery, Veterans Administration, who assumes no responsibility for the opinions expressed or the conclusions drawn by the author.

†Chief, Neuropsychiatric Services, Veterans Administration Hospital.

‡All patients in this series were treated by the standard operation of Freeman and Watts. Dr. John S. Hodgson was the neurosurgeon.

§Of this number only 2 deaths were directly attributable to intracranial complications of the surgical procedure.

leukotomy, manifest the extreme of unacceptable behavior found before the operation.

The evaluation of this procedure is made uniquely difficult and rather arbitrary by another factor, and that is that the one most directly concerned with the treatment — the patient — has not participated actively in the evaluation of the results. The opinions of the relatives and of the doctors and the nursing staff concerning this procedure are known, but I must confess that the opinion of the patient himself is not known. For, in practically every case, the patient, when questioned, professes not to know anything about any surgical procedure to which he has recently been subjected. This is particularly true when the patient, postoperatively, shows a great deal of dullness, indifference and apathy. Patients who do recognize, as indicated by their replies to questions, that an operative procedure has been carried out on the brain seem to have little or no understanding of the operation or the results to be attributed to it.

Before proceeding farther I wish to make note of the fact that the group of patients under consideration were, with 1 exception, schizophrenics whose illness and hospitalization was of two to twenty years' duration at the time of operation. The results may therefore not be directly comparable with the series of results reported for nonschizophrenic patients, or for schizophrenic patients whose illness has been of relatively brief duration.

Those who have participated in the selection of these patients for leukotomy, or who have had them under care before the operation, are familiar with the preoperative clinical picture. There are no significant exceptions in any of the 42 patients so far as the characteristics mentioned below are concerned. For those who are not familiar with their preoperative clinical picture I may say that, with one exception, they have all been schizophrenics hospitalized for two years or more — generally five years or more. The male patients, for the greatest part, were resident in the building for the most disturbed patients. They were, before operation, excited, assaultive, combative and destructive. Most were hallucinated and deluded and, characteristically, appeared to be tortured, agonized and distressed beyond measure by their morbid mental experiences. Most had made one or more suicidal attempts, and most had required, for greater or shorter periods, mechanical restraint, chemical restraint or seclusion. With but 1 or 2 exceptions, their previous treatment had included convulsive therapy or insulin-shock therapy or both. Most had not been outside a mental hospital for two years, five years or — in 1 case — about twenty years. Their children had forgotten them. Their wives and parents had, in many cases, adjusted their lives so as not to include the patient in their present or future reckonings. By all criteria that are now known, the future for these patients offered only a continuation of the recent past.

This, then, is a composite clinical picture of the patients in the series before operation. Regarding the postoperative results I wish first to consider the group of patients who are still in the hospital.

Taking one of this group in whom the result is rather more favorable than most, I will arbitrarily select the order and emphasis to be given to the clinical features in the case. This patient is now neat in personal appearance and tidy, eating and sleeping well. The reports of the nurses indicate that, at various times, he attends dances, goes swimming, listens to music, views television shows, goes bowling, reads and visits the occupational-therapy shops. He works on the hospital chicken farm, where he gathers eggs, feeds and waters chickens and cleans the chicken house. When interviewed by me, he stated that he felt relaxed and was no longer hallucinated or delusional; he recalled, without much show of concern, his rather prolonged stay, before his operation, on a ward for disturbed patients. He remembered that it was noisy there and that he could not read. He is polite in his manner today, and answers questions promptly but slowly. He is correctly oriented. He has ground privileges. In response to leading questions he tells me that he was operated on in Ward 2-E: "They call it lobotomy. It means cutting the nerves in my head. I woke up and had a bandage on my head. No, I don't see much difference in the way I feel."

To a greater or lesser extent the clinical results described above are to be found in about two thirds of the group of patients remaining in the hospital. If still hallucinated, they are no longer disturbed by these hallucinations. They no longer require restraint or seclusion. They either have ground privileges, go home on short visits, or are able to live in the hospital under conditions involving relatively little supervision. They participate in the activities — movies, dancing, bowling and so forth — that give most people pleasure. Whether these activities give pleasure to the patients under discussion is difficult to determine. For these patients are not only no longer distressed by their mental conflicts but also seem to have little capacity for any emotional experiences — pleasurable or otherwise. They are described by the nurses and the doctors, over and over, as dull, apathetic, listless, without drive or initiative, flat, lethargic, placid and unconcerned, childlike, docile, needing pushing, passive, lacking in spontaneity, without aim or purpose, preoccupied and dependent.

In the evaluation of these results, with what is one to be most impressed — with the contrast between the tormented, assaultive, maniac and the placid, docile, childlike person who goes to dances, reads, listens to music and goes to the movies? This contrast is indeed both marked and

impressive. However, I cannot but recall the remark of the relative of a patient, as reported in an English journal, that the patient seemed to have lost his soul in the process of being changed from one state to the other. I am further reminded of the story about the farmer who made a pact with the devil. Here, however, it is the surgeon, rather than the patient, who appears to have made the pact, and, unfortunately, there is no Daniel Webster to release the patient from his pact.

I should like to consider the patients who have left the hospital and examine more closely the types of adjustment that, in the records, are reported as "satisfactory." These cases are as follows.

M. G. has been home for 1 year and 9 months. During this period he has been married, and his mother reports that he and his wife are very happy together. She further states that if people did not know that the patient had been in a mental hospital they could not tell it by seeing him or talking to him now. The patient, a musician with some talent before the onset of his psychosis, accepted equably, upon his release from the hospital, his rejection as a student by a music school. The school believed that he had not had enough practice in recent years to be able to profit by further intensive training. He went instead to a school of optics and completed the course in a year. There was no job in optical work readily available, and he did not persist in efforts to find employment in his new trade. Instead he got temporary work in the post office. At present he is going to an upholstery school and has been promised a job by his brother, who owns an upholstery shop.

I. R. has been at home continuously for exactly 2 years. His wife, who remained faithful to him throughout the long period of his psychotic illness and visited him regularly in good weather and bad, whether abused by the patient or not, has bought a house with the accumulated retirement pay of the patient as a down payment. She has remodeled the house so that she collects rent for half of it, and this, in addition to retirement pay, is their only source of income. The patient spent 6 to 8 months at the time of release from the hospital at the Boston Community Work Shop, but it was reported that he was unable to learn any trade. The social-service workers have found several jobs for him, which he either refuses or loses before he starts because he insists on informing his prospective employer that he has had half his brain cut out, that he has been in insane asylums for several years, that he is legally incompetent and that his wife holds all his money. He insists on telling obscene jokes in the presence of strangers and in using profanity freely. Last summer, at a local beach, he distressed a woman neighbor because he calmly placed himself in a conspicuous place on the beach where he unabashedly viewed the charms of the women passing by on the boardwalk overhead. The patient's wife calmed the irate neighbor by telling her that her husband did the same thing, except that he did it furtively. According to the wife, the patient has built a picket fence around their property and puts up shelves and builds bookcases around the house. Objective reports are, however, less favorable and indicate that he is slow at any work he undertakes, that his results are poor, that he does not appear to have a care in the world and that nothing seems to bother him. He shows no sense of responsibility and no sense of urgency to assume the role of father and husband. The opinion of the wife concerning the operative procedure is of interest. I asked her whether , if she had it to do over again, she would again give permission for the operation. Her response came without a moment's hesitation and carried with it a note of conviction. "Yes, indeed. Now we have a home together and are a family again."

Another patient, a woman, has been home for 6 months. Still delusional, but not aggressive about her delusions, she is a slovenly housekeeper, with no sense of responsibility to her husband and children. It is only because her husband is a mild, passive man, willing and able to arrange his working hours so that he can be home much of the day, that she can continue to live outside the hospital.

F. F. has continued to live outside the hospital, but the circumstances under which this has been made possible are significant. Immediately after the operation, his stepmother was hostile to any plans to bring him home, but an aunt agreed to take him in. He was reported as being friendly and cooperative, but without much drive. Like many of these patients, he was described as being "inconsiderate." By this term, it was meant that he left the water running in the bathroom, neglected to close the outer door on cold days and left the radio blaring for hours on end. After a few months of such behavior at his aunt's home it began to appear that his further stay there would not be welcome. About this time he married a girl he had met since his leukotomy. From the fact that his wife is reported to have had a harelip, one would assume that she would be more tolerant than the aunt of one so handicapped as the patient. This has proved to be the case, and in spite of the fact that the patient continues to be unable to hold a job and to be generally irresponsible, he and his wife appear to be happy and contented.

L. F. lives on the farm of his overprotective mother. While he was in the hospital, his mother used to visit me frequently—pleading, cajoling and demanding to take her son home. Now he is her little boy again. He does simple errands, enjoys playing with boys of 7 and 8 years old in the neighborhood, and is himself shy, childish and dependent. He cannot learn to do any but the very simple chores about the farm. His mother, however, is entirely satisfied.

From the report of another patient it is noted that his mother does not care if he never goes to work again because, as she puts it, she is willing to support him for the rest of his life.

Another continues unemployed after 5 months but is otherwise well adjusted at home. Still another lives with an easy-going mother of limited intelligence. The family are pleased to have him home. He goes to the movies but is otherwise without initiative, and is poorly oriented and mildly confused. His mother writes, "He is no good for any job that would pay money."

Another patient helps his brother in his grocery store by sweeping floors and stocking shelves but is not permitted to wait on the customers.

Discussion

It might be desirable to mention a few minor points concerning which interest has been expressed. Since leukotomy may have, as one of its effects, the reduction of inhibition on the part of the patient, the question of postoperative sexual behavior has been raised. From the information derived from this group of patients it appears that there has been no aggressive or objectionable sexual behavior in any of the patients. There have been open masturbation, preoccupation with obscene jokes, and obscene speech and uninhibited staring at female passers-by. One or two female personnel in the hospital have reported being "annoyed" by these patients, without detailing the type of annoyance, but when the patient was spoken to by his physician there was no repetition. The wife of a patient reports that his sexual interests in her are diverted if she simply turns him over in bed so that he faces the wall.

Some of these patients are extravagant with money and seem to have little sense of value. Others are not. Some are extravagant at first but later learn to take care of money.

The inability of patients to learn to carry out any but the most simple tasks, is noted repeatedly by hospital workers. This fact has considerable bearing on the difficulties the patients have in finding and holding employment.

The point about this study that has impressed me most is that not one of 42 patients has been able to make a fully independent social and economic adjustment after operation. None are completely self-supporting. All require a protective environment — either in the hospital or at home — for survival. All have had to borrow something from the ego of a devoted wife, son, mother or sister. These patients as a group remind me of a watch that has stopped. If one shakes it vigorously the watch is apt to tick a few times, and the tick sounds like that of a watch in good repair, but it runs down almost immediately and stops. In fact, I have not been able to wind these patients up sufficiently so that they can run like an eight-day clock, or for that matter, even for a day.

I recognize that in this brief presentation, I have not discussed the contributions and limitations of medical rehabilitation and social-service activities. Important as these topics are, the limited time at my disposal makes such neglect necessary.

In this presentation I have deliberately described at some length what must be considered the less desirable clinical results of leukotomy. I have done this because most people interested in the subject have been so impressed by the dramatic changes in behavior produced by leukotomy — from a wildly excited, assaultive, combative, suicidal psychotic to a mild-mannered, docile, "well behaved" patient —that they have, perhaps, overlooked the very real and permanent losses to the integrity of the personality. I think it should be re-emphasized that by psychosurgery an organic brain-defect syndrome has been substituted for the psychosis, but the psychosis has not been cured. Psychosurgery, in my opinion, is a temporary therapeutic expedient, justifiable only because knowledge of specific therapy is still not sufficiently developed or available to effect true cures in many of these patients.

It seems to me that one should be hesitant in recommending leukotomy for the chronic schizophrenic patient unless he is chronically assaultive, combative, homicidal or suicidal and his very life is jeopardized by an uninterrupted continuation of this state, or, in selected cases, the return of the psychotic patient to the family circle of a distraught mother or other relative can be justified for humane reasons. The emotional need of such a mother for her son — morbid though it be — can be satisfied after leukotomy of the son, as I have indicated in some of the cases discussed above.

MEDICAL PROGRESS

EXFOLIATIVE CYTOLOGY*

HOWARD ULFELDER, M.D.†

BOSTON

THE past eight years have witnessed widespread revival of the study of body fluids as an adjunct in the detection of cancer. The focus of attention in these fluids has been on the cellular constituents — the cells that have become separated from body surfaces by the natural process of desquamation. An apt phrase, "exfoliative cytology," has been coined by Papanicolaou to describe this field of investigation. It is eminently fitting that he should be the one to do so, for Papanicolaou's original painstaking observations are the firm foundation on which this science has been built.

Sporadic attempts to use exfoliated cells as an indication of underlying disease have been reported in the medical literature of the last hundred years. The results were confusing and of low accuracy. Then, in 1917, Stockard and Papanicolaou[1] described the first of a long series of observations on the cellular pattern of aspirated vaginal fluid of rodents. The course pursued in these studies and their culmination in the recognition of cells from malignant growths in the human female genital tract is outlined in Papanicolaou's[2] review of 1946. From his reports, one conclusion is inescapable and crystal-clear: a high degree of accuracy in the interpretation of exfoliative cytologic preparations is possible only after one is *thoroughly familiar* with the numerous cellular variations that may be found in benign states.

The number of scientific papers on this subject shows a steady increase every month and proper evaluation of each contribution becomes more and more difficult. It may be helpful to epitomize the procedure in outline form in its simplest terms and

*Presented under the title "Evaluation of the Papanicolaou Technic in the Diagnosis of Malignant Disease" at the annual meeting of the Massachusetts Medical Society, Worcester, May 24, 1949.
From the Vincent Memorial Hospital Laboratory of the Massachusetts General Hospital.

†Clinical associate in surgery, Harvard Medical School, assistant surgeon, Massachusetts General Hospital; gynecologist, Pondville Hospital.

to measure each new report in the light of whatever feature it emphasizes.

1. Preparation
   a. Collection
   b. Fixation
   c. Staining
2. Interpretation

Thus there are two basic steps in any cytologic study — the preparation of a slide and its interpretation. Preparation involves collection of material, fixation and staining. Whatever the method of collection, it must have as its goal the transfer to a glass slide of a representative specimen of cells well preserved and recently shed from the area under investigation. The process of fixation should be able to maintain cellular detail for an indefinite period without destroying or removing an appreciable number of the cells originally present on the slide. Staining and counterstaining should provide sufficient contrast to bring out minute nuclear and cytoplasmic morphology, again without destroying or removing cells in the process.

Interpretation, the second basic step, should be restricted to persons who have received special training for that purpose and who are in a position to improve their accuracy by constant practice. Facility in the recognition of abnormal cells can be developed in no other way; the occasional microscopist cannot hope to do so. With this outline and these fundamental principles in mind, some of the literature on exfoliative cytology is reviewed. This is best done if the body systems are considered separately.

Female Genital Tract

Although a brief note in 1928[3] has recorded Papanicolaou's earliest conviction that cancer of the uterus sheds recognizable cells into the vaginal fluid, it was not until 1941 that Papanicolaou and Traut[4] made a complete report, including both the description of their technic and criteria used in diagnosis. A monograph published in 1943[5] presents their material in detail. Within a few years Meigs,[6] in Boston, Jones,[7] in New York, and Ayre,[8] in Montreal, reported extensive trial of the method and complete agreement with Papanicolaou's conclusions. These early papers are concerned almost exclusively with the problem of interpretation. All agree that the more experienced the cytologist and the more smears examined on a given patient, the greater the likelihood of finding cancer when it is present. Their cytologic accuracy ranged around 90 per cent for patients with carcinoma of the cervix and between 80 and 90 per cent for cases of carcinoma of the fundus. They pointed out that errors of another type were also encountered, when cytologic reports of malignant lesions that could not be confirmed pathologically were rendered. A number of other clinics[9–11] have now studied the method and reported their results; no one who has given it an honest trial has condemned it. It should be noted that there is considerable variation in methods of statistical analysis, for some papers list cytologic data and calculate percentages of pathological confirmation, whereas others report cases proved to be cancer and calculate percentages of cytologic accuracy. The Vincent Memorial Hospital group uses only the first cytologic report on each patient in its statistics — a method designed to permit evaluation of exfoliative cytology as a screening procedure.

Almost every publication in this field has included cases in which malignant cells were found in the vaginal fluid and the lesion has proved to be preinvasive cancer of the cervix (carcinoma-in-situ). This fact is of vital importance and, fortunately, is not dependent on mere chance for a comparison between smear and biopsy[12] in a group of 181 proved cases of cervical cancer has demonstrated that each of these methods tends to pick up the lesions that the other one misses. Thus, the smear is of great value in revealing extremely early cancer of the cervix, and in this series, by the use of *both* methods of diagnosis, only 3 of the cases were missed at the time of *first* examination.

The interpretation of the vaginal smear after radiation therapy to the genital tract is a special study in itself. The cellular changes noted under these conditions are described by Graham.[13] These effects are present in both the normal and the malignant cells. When cases were classified according to degree of radiation response as judged by these cytologic changes, remarkable correlation with their clinical behavior was apparent. Graham concluded that the smear may be of great prognostic value in cases of cancer of the cervix treated by radiation.

It is obvious from Graham's paper that a trained observer can, without great difficulty, recognize malignant cells after radiation or other therapy. Repeated cytologic check on such patients may lead to the discovery of persistent or recurrent disease. Over 10 per cent of Meigs's[14] 1015 cases were patients in the gynecologic tumor follow-up clinic, and one of his protocols describes a case in which smears were consistently positive for nine months before recurrent disease of the cervix could be histologically confirmed.

Failure to achieve 100 per cent accuracy has inevitably led to modifications in the method of preparation of the cytologic specimen. As early as 1943 Papanicolaou and Marchetti[15] described the use of a small cannula to aspirate fluid directly from the endocervix and the endometrial cavity. Ayre[16] also has preferred to collect his material from the region of the external cervical os, originally by aspiration and more recently by rotatory scraping with a special wooden spatula. This he calls, quite rightly, a "surface biopsy." Hunter[10] has used the Papanicolaou

technic but also collects surplus vaginal fluid in fixative and sections and stains the resulting pellet in orthodox pathological fashion. Each method of preparation produces its own characteristic cytologic pattern, and each demands experience before accuracy is possible.

There is universal agreement that smears should be fixed *immediately* and not allowed to dry. Ether and alcohol, alcohol alone, Schaudin's solution and others have been used with equal success. Staining is usually by Papanicolaou's[17] method, although some prefer hematoxylin and eosin.

Although the exponents of exfoliative cytology point out repeatedly wherein it deviates from the ideal, it is from the pathologist that one expects constructive criticism. Several articles and a handbook of diagnosis by Gates and Warren[18] and their associates present the attitude of the practicing pathologist. They warn against its use in place of other well established methods of diagnosis and decry any complacency founded on cytologic reports alone. In evaluating its use as a screening test for women without symptoms,[19] they question whether the low yield is economically justified. However, they agree that some cases of cancer are unquestionably discovered earlier by this means than would otherwise be possible, and they point out that these investigations have given desirable impetus to the study of very early cancer.

The dramatic possibilities inherent in the cytologic method have not failed to rouse the interest of writers who attempt to interpret things medical for the public at large. At least two articles[20, 21] have appeared in women's magazines. The facts presented are scrupulously accurate, but their selection and accompanying text are so uncritical that one is left with the impression that any physician who cannot or will not perform this simple test on his patient is derelict in his duty. Such publicity, unfortunately, creates resentment within the ranks of the medical profession and a bias that will have to be overcome by complete honesty of reporting in professional journals.

Pulmonary Tract

In 1946 Herbut and Clerf[22] reported a series of 30 patients with proved carcinoma of the lung in whom bronchoscopic aspirations or washings were studied by Papanicolaou's technic of fixation and staining. In 22 cases (73 per cent) malignant cells were found. Similar study of expectorated sputum in 7 cases revealed cells only once. No false-positive reports are recorded, but the authors draw attention to 7 cases in which cytologic examination showed cancer although bronchoscopy had failed to reveal a tumor. A more recent summary of Herbut's work shows 105 positive smears in 118 cases of cancer of the lung, an accuracy of 89 per cent. A false-positive report was made in 4 additional cases.

Others have not found the examination of sputum so unrewarding. Papanicolaou[23] noted malignant cells in the sputum of 88 per cent of 25 patients with cancer of the lung, and Woolner[24] states that sputum or bronchial secretion proved equally satisfactory.

McKay[25] considers saline washings through the bronchoscope unsatisfactory. He and his associates have collected secretions on a cotton plug in the aspirator and have made their smears from this.

Every paper points out that Dudgeon and Wrigley,[26] in 1935, reported malignant cells in the sputum of 68 per cent of patients in a series of 38 cases with proved carcinoma of the lung. This work is quite obviously independent of that of Papanicolaou. It is most interesting to retrace the steps that led them to this study, for one finds it to be an adaptation of a technic reported by Dudgeon and Patrick[27] in 1927, in which scrapings of suspicious tissue from a variety of sources were spread on a slide and rapidly fixed, stained and examined. It appears that a pathologist, in his attempts at tumor diagnosis with smaller and smaller biopsies, has reached common ground with the cytologist.

Upper Gastrointestinal Tract

The preparation of cellular spreads of gastric fluid must take into account certain factors not met in the secretion of the female genital and pulmonary tracts. Gastric fluid is less viscid, and the cells are much less numerous. Digestive ferments are present that will rapidly destroy the cells one wishes to study. Moreover, aspiration of stomach contents without roentgenologic check on the position of the tube runs the risk of failing to obtain a representative sample of the cells in the distal third of the stomach — an area where gastric carcinoma is most likely to occur.

Papanicolaou and Cooper[28] stress the importance of rapid fixation. They mix gastric fluid with an equal volume of 95 per cent alcohol, centrifuge for twenty minutes, spread the sediment on slides prepared with Mayer's albumen and then fix and stain them in their usual fashion. In a series of 27 cases of gastric cancer, positive smears were reported in 10 and suspicious ones in 7 others. There were no false-positive reports, but 9 of the 110 benign fluids were considered suspicious. Pollard and his associates,[29] using the same technic, found malignant cells in 35 to 40 per cent of patients with cancer of the stomach. They point out that satisfactory cytologic preparations are impossible in the presence of obstruction and gastric retention. This has also been emphasized by Ulfelder, Graham, and Meigs[30] who reported a high degree of accuracy (correct smears in 12 out of 14 patients with cancer of the stomach) when modifications in the method of collection were introduced. These include the use of a tube with additional openings in it and the introduction of physiological saline solution into the stomach in an effort to obtain a representative sample from the

entire organ. They stress the necessity of personal attention to the details of collection and preparation. Occasional false-positive smears were found by both Pollard and Ulfelder.

The malignant cells in gastric smears may be detected by application of the same criteria of abnormality postulated in the examination of other fluids. Most of the normal cells, however, are not gastric in origin, and familiarity with this normal picture is essential for accuracy.

Urinary Tract

In dealing with urine one finds again that centrifugation is necessary to concentrate the cells in a small amount of sediment. Here also the use of albumen on the glass slides helps to retain the secretion during fixation and staining. Papanicolaou and Marshall[31] add 95 per cent alcohol to freshly collected urine to retard cellular disintegration, although Chute and Williams[32] discard this step in favor of immediate centrifugation and alcohol fixation of the sediment only.

Interpretation of urine smears is somewhat complicated by the lack of differentiation normally seen in transitional epithelium. Benign multinucleated cells are common. Moreover, many stages of activity are represented in any series of new growths of the urinary bladder, and a spectrum of grading is possible which crosses almost imperceptibly the line between benignancy and malignancy. Papanicolaou[33] reports 240 cases of which 76 are considered to have had carcinoma of the urinary tract. Fifty-eight (76 per cent) were diagnosed correctly by the smear. Three positive reports were rendered in the 164 patients considered not to have cancer, although 2 of them did have benign papillomas.

A much lower accuracy is reported by Chute and Williams. Only 55 per cent of cancers were detected, and there were 12 per cent false-positive reports. Most of the tumors missed were of low malignancy. Recently, Foot and Papanicolaou[34] reported a case of histologically proved noninvasive cancer of the renal pelvis invisible grossly but detected preoperatively by the cytologic method.

Both reports quoted in the paragraph above point out that carcinoma of the prostate may shed cells into the urine. Prostatic secretion collected by massage and immediately smeared, fixed and stained has been studied by Herbut and Lubin[35] and also by Albers and his co-workers.[36] Both report an accuracy of over 85 per cent in cases of cancer if secretion is ample for smearing. A few positive smears that could not be confirmed histologically were also encountered.

Serous Cavities

Prior to the development of Papanicolaou's technic, more serious endeavor was applied to this type of fluid than to any other. A number of excellent reports[37, 38] are available, particularly since 1928. The majority of pathologists centrifuge the fluid and fix and section the residue. The criteria used in diagnosis are dependable only when clusters of tumor cells in some recognizable architecture are present, although individual morphologic details have been carefully assessed and useful observations made on the nucleolar-nuclear ratio in benign and malignant cells.

A recent paper,[39] in which smears of sediment were used, reports an accuracy of only 56 per cent in cases in which cancer could be assumed to have involved the serous surfaces. This figure is no improvement over the 65 to 70 per cent accuracy reported in the past. There was, however, only 1 false-positive smear in this series whereas this type of error was common (25 to 50 per cent) in previous reports. One important deviation from Papanicolaou's technic should be noted in the procedure used by Phillips and McDonald[39]: the smears were allowed to dry before fixation. In a series of 91 cases in which Papanicolaou's method was used without modification, the Vincent Memorial Laboratory[40] found malignant cells in 35 out of 45 cases. Four other positive smears were not corroborated histologically.

Other Fluids

The investigative curiosity of cytologists has extended to every conceivable material. It is known that rectal swabbings, duodenal aspirates, spinal fluid, ocular humors and many others are being examined. No formal reports have appeared, but it is probable that the fundamental technical principles are similar to those already described, with modifications to suit the character of each type of specimen.

Discussion

It is obvious that exfoliative cytology can lead to the discovery of cancer in a variety of body areas, even when the lesion is invisible in size or histologically noninvasive. The results are most accurate when slides are prepared by a person interested in the procedure and willing to give time and attention to details that may facilitate interpretation, and when the slides are examined by someone thoroughly familiar with the cellular pattern of that particular fluid, prepared in that particular way.

Even under the best conditions available today there are two types of error — the false-negative and the false-positive cytologic report. The danger of the former is the unwarranted sense of security it gives to both patient and physician; it has analogies in any diagnostic procedure used in the cancer-detection clinic. This danger is so real that one must emphasize constantly the fact that failure to find cancer does not guarantee its nonexistence. It may be worth while in this connection to abandon any terminology of reporting that uses the words "negative," "normal," et cetera and to substitute phrases such as "no malignant cells found."

The danger of the false-positive report is that radical therapy may be instituted with no attempt to find confirmatory evidence. Such patients should be subjected to frequent re-examination and managed according to a well planned study designed to determine exactly whence the abnormal cells arose. Serial section of any removed tissue is an essential feature of this program. As Gates and Warren point out, knowledge of the natural history of most malignant lesions is woefully meager in the early stages of disease. Now there is available a method that will permit more study of this type of case than has ever before been possible.

Looking at exfoliative cytology from quite another point of view, one may consider the chief disadvantage of the method to lie in its failure to *localize* the disease. For example, in a patient with malignant cells in the sputum and a small area of consolidation in one lung field, it is only the laws of probability that permit consideration of that area as the source of the cells. This will be true regardless of the eventual accuracy of the method and makes it essential that one discriminate very carefully in choosing between surgical procedures for confirmation and localization and surgical procedures for cure.

It may be best to think of the method as one that permits selection of some patients who are almost certain to have malignant lesions, for a repeatedly positive report from dependable sources is seldom wrong and warrants every possible effort at confirmation. By the same token, on the rare occasions when the malignant potential of a known tumor is in question, a positive smear should point the way to adequate cancer therapy.

264 Beacon Street

References

1. Stockard, C. R., and Papanicolaou, G. N. Existence of typical oestrus cycle in guinea pig—with study of its histological and physiological changes. *Am. J. Anat.* **22**:225–283, 1917.
2. Papanicolaou, G. N. General survey of vaginal smear and its use in research and diagnosis. *Am. J. Obst. & Gynec.* **51**:316–328, 1946.
3. *Idem.* New cancer diagnosis. In *Proceedings of the Third Race Betterment Conference, January 2-6, 1928.* 748 pp. Battle Creek, Mich.: Race Betterment Foundation, 1928. Pp. 528-534.
4. Papanicolaou, G. N., and Traut, H. F. Diagnostic value of vaginal smears in carcinoma of uterus. *Am. J. Obst. & Gynec.* **42**:193–206, 1941.
5. *Idem. Diagnosis of Uterine Cancer by the Vaginal Smear.* 47 pp. New York: Commonwealth Fund, 1943.
6. Meigs, J. V., Graham, R. M., Fremont-Smith, M., Kapnick, I., and Rawson, R. Value of vaginal smear in diagnosis of uterine cancer. *Surg., Gynec. & Obst.* **77**:449–461, 1943.
7. Jones, C. A., Neustaedter, T., and MacKenzie, L. L. Value of vaginal smears in diagnosis of early malignancy: preliminary report. *Am. J. Obst. & Gynec.* **49**:159–168, 1945.
8. Ayre, J. E. Vaginal cell examination as routine in diagnosis: study of vaginal and cervical cytology as related to abnormal growths. *South. M. J.* **39**:847–852, 1946.
9. Gates, O., and Warren, S. Vaginal smear in diagnosis of carcinoma of uterus. *Am. J. Path.* **21**:567–601, 1945.
10. Hunter, W. C., and Richardson, H. L. Cytologic recognition of cancer in exfoliated material from various sources: useful modifications of Papanicolaou technique. *Surg., Gynec. & Obst.* **85**:275–280, 1947.
11. Isbell, N. P., Jewett, J. F., Allen, M. S., and Hertig, A. T. Correlation between vaginal smears and tissue diagnosis in 1045 operated gynecologic cases. *Am. J. Obst. & Gynec.* **54**:575–583, 1947.
12. Graham, R. M., Sturgis, S. H., and McGraw, J. Comparison of accuracy in diagnosis of vaginal smear and biopsy in carcinoma of cervix. *Am. J. Obst. & Gynec.* **55**:303–307, 1948.
13. Graham, R. M. Effect of radiation on vaginal cells in cervical carcinoma. I. Description of cellular changes. II. Prognostic significance. *Surg., Gynec. & Obst.* **84**:153–173, 1947.
14. Meigs, J. V., Graham, R. M., Fremont-Smith, M., Janzen, L. T., and Nelson, C. B. Value of vaginal smear in diagnosis of uterine cancer: report of 1015 cases. *Surg., Gynec. & Obst.* **81**:337–345, 1945.
15. Papanicolaou, G. N., and Marchetti, A. A. Use of endocervical and endometrial smears in diagnosis of cancer and other conditions of uterus. *Am. J. Obst. & Gynec.* **48**:421, 1943.
16. Ayre, J. E. Selective cytology smear for diagnosis of cancer. *Am. J. Obst. & Gynec.* **53**:609–617, 1947.
17. Papanicolaou, G. N. New procedure for staining vaginal smears. *Science* **95**:438, 1942.
18. Gates, O., and Warren, S. *A Handbook for the Diagnosis of Cancer of the Uterus by the Use of Vaginal Smears.* 182 pp. Cambridge, Mass.: Harvard University Press, 1947.
19. Lombard, H. L., Middleton, M., Warren, S., and Gates, O. Use of vaginal smear as screening test. *New Eng. J. Med.* **239**:317–321, 1948.
20. Howard, C. Cancer of womb. *Woman's Home Companion.* October, 1947.
21. White, W. L. Killer of women. *Ladies' Home Journal.* November, 1947.
22. Herbut, P. A., and Clerf, L. A. Bronchogenic carcinoma: diagnosis by cytologic study of bronchoscopically removed secretion. *J. A. M. A.* **130**:1006–1012, 1946.
23. Papanicolaou, G. N. Diagnostic value of exfoliated cells from cancerous tissues. *J. A. M. A.* **131**:372–378, 1946.
24. Woolner, L. B., and McDonald, J. R. Diagnosis of carcinoma of lung: value of cytologic study of sputum and bronchial secretions. *J. A. M. A.* **139**:497–502, 1949.
25. McKay, D. G., Ware, P. F., Atwood, D. A., and Harken, D. E. Diagnosis of bronchogenic carcinoma by smears of bronchoscopic aspirations. *Cancer* **1**:208–222, 1948.
26. Dudgeon, L. S., and Wrigley, C. H. On demonstration of particles of malignant growth in sputum by means of wet-film method. *J. Laryng. & Otol.* **50**:752–762, 1935.
27. Dudgeon, L. S., and Patrick, C. V. New method for rapid microscopical diagnosis of tumours, with account of 200 cases so examined. *Brit. J. Surg.* **15**:250–261, 1927.
28. Papanicolaou, G. N., and Cooper, W. A. Cytology of gastric fluid in diagnosis of carcinoma of stomach. *J. Nat. Cancer Inst.* **7**:357–360, 1947.
29. Pollard, H. M., Bryant, H. C., Block, M., and Hall, W. C. Diagnosis of gastric neoplasms: by cytologic examination of gastric secretions. *J. A. M. A.* **139**:71–74, 1949.
30. Ulfelder, H., Graham, R. M., and Meigs, J. V. Further studies on cytologic method in problem of gastric cancer. *Ann. Surg.* **128**:422–424, 1948.
31. Papanicolaou, G. N., and Marshall, V. F. Urine sediment smears as diagnostic procedure in cancer of urinary tract. *Science* **101**:519, 1945.
32. Chute, R., and Williams, D. W. Experiences with stained smears of cells exfoliated in urine in diagnosis of cancer in genito-urinary tract: preliminary report. *J. Urol.* **59**:604–613, 1948.
33. Papanicolaou, G. N. Cytology of urine sediment in neoplasms of urinary tract. *J. Urol.* **57**:375–379, 1947.
34. Foot, N. C., and Papanicolaou, G. N. Early renal carcinoma in situ: detected by means of smears of fixed urinary sediment. *J. A. M. A.* **139**:356–358, 1949.
35. Herbut, P. A., and Lubin, E. N. Cancer cells in prostatic secretions. *J. Urol.* **57**:542–551, 1947.
36. Albers, D. D., McDonald, J. R., and Thompson, G. J. Carcinoma cells in prostatic secretions. *J. A. M. A.* **139**:299–303, 1949.
37. Quensel, U. Zur Frage der Zytodiagnostik der Ergüsse seröser Höhlen. Methodologische und pathologisch-anatomische Bemerkungen. *Acta med. Scandinav.* **68**:427–457, 1928. Zytologische Untersuchungen von Ergüssen der Brust- und Bauchhöhlen mit besonderer Berücksichtigung der karzinomatösen Exsudate. *Ibid.* **68**:485–501, 1928.
38. Foot, N. C. Identification of tumor cells in sediments of serous effusions. *Am. J. Path.* **13**:1–12, 1937.
39. Phillips, S. K., and McDonald, J. R. Evaluation of various examinations performed on serous fluids. *Am. J. M. Sc.* **216**:121–128, 1948.
40. Vincent Memorial Laboratory, Massachusetts General Hospital. Unpublished data.

CASE RECORDS OF THE MASSACHUSETTS GENERAL HOSPITAL

Weekly Clinicopathological Exercises

FOUNDED BY RICHARD C. CABOT

TRACY B. MALLORY, M.D., *Editor*

BENJAMIN CASTLEMAN, M.D., *Associate Editor*

EDITH E. PARRIS, *Assistant Editor*

CASE 35321

PRESENTATION OF CASE

First admission. A twenty-nine-year-old married woman entered the hospital because of a nontender lump in her left breast.

She noticed this lump about six weeks before entry, and it apparently had not increased in size since then. There had not been any bleeding from the nipple or soreness under the arm. The patient was nine and a half months post partum, having delivered a normal girl, her first child. She did not nurse the child because she did not believe she was emotionally suited to nursing. There was no weight loss or anorexia.

Except for the local lesion in the left breast, physical examination was entirely negative. The left breast was filled with a firm, grape-like cluster of nodules, densest in the inner middle quadrant. It was nontender, not fixed to the skin or chest wall and did not produce blood at the nipple on pressure. There was a bean-sized nodule in the left axilla.

A radial incision was made medial to the areola, and the involved area of breast tissue was excised. Immediate pathological examination showed no evidence of cancer, and the specimen received in the laboratory measured 5 by 4.2 cm. and was diagnosed as sclerosing adenosis and periductal mastitis.

Second admission (ten months later). Soon after operation a small swelling developed near the operative incision, but this was considered to be an operative sequela. The patient received several doses of testosterone and then stilbestrol, with some improvement. However, because of the persistence of the mass and her continued anxiety, an aspiration was performed with return of old blood clot. It was believed that the lesion was a hematoma, and she was therefore admitted to the hospital for evacuation of it.

A circumareolar incision was made in the upper inner corner of the left breast. A considerable amount of blood clot was evacuated, together with a good deal of bright blood, and the incision was extended down along the line of the previous incision. The tissue was so necrotic and the bleeding so brisk that eventually a mastectomy was performed.

Third admission (four months later). After discharge the patient felt well and gained 6 pounds. About eight weeks before admission, however, she began to feel a slight pain in the upper outer quadrant of the right breast. She was examined by her physician seven weeks before entry, but no mass was palpable; however, the pain continued. One week before admission the patient was re-examined, and a mass was found in the right breast. She was therefore referred back to the hospital.

Physical examination showed an area of thickening, 2 by 3 cm., which was slightly firm, nontender and not well defined, in the upper, outer quadrant of the right breast. The scar of the left mastectomy was well healed.

On the second hospital day exploration of the right breast was performed.

DIFFERENTIAL DIAGNOSIS

DR. GRANTLEY W. TAYLOR: This is to my knowledge the briefest physical examination of a patient that I have ever seen in a clinicopathological conference. So this case will simply form some sort of text on which we can hang a number of not too brilliant diagnoses.

Here is a patient with something the matter with her breast, which was explored, who got into trouble postoperatively and in whom a mastectomy finally had to be done. I think that is deplorable. The findings on exploration — sclerosing adenosis and periductal mastitis — represent some of the disintegrated segments of the old category of chronic cystic mastitis. Foote and Stewart[1] subdivided that clinical group of diseases, and I noticed with a good deal of amusement that often one of the residents in pathology is apt to make seven or eight diagnoses in that category on a single patient. The problem of the relation of this disease to malignant neoplasm is one that is very poorly clarified. Dr. Shields Warren,[2] some years ago, undertook to find out what relation this general group of diseases called chronic cystic mastitis bears to the subsequent development of cancer. In reviewing patients who had had partial breast excisions or partial amputations that he had followed up he found that the incidence of cancer was definitely increased. The series was large enough to be statistically valid. Unfortunately, from my viewpoint, he did not subdivide the disease into the various subdivisions that Foote and Stewart recommend. Therefore, it is impossible to say which one of these various categories is the most likely

to be associated with subsequent development of the malignant process. He did divide the cases into age groups and found that if cystic disease had been manifested in the twenties, the likelihood of subsequent cancer was vastly greater than if the first evidence of disease did not appear until the forties or fifties. In the latter age group the incidence of subsequent cancer was almost identical with that of a control population.

We have a young woman who had such a diagnosis made in relation to her breast. It was removed, and she reappeared rather promptly with an area in the other breast. This had first put in its appearance as a painful area. Nothing is said in the record about whether the pain was related to the menstrual cycle in any way. I am inclined to believe that probably it was, because most cases of breast pain that do not have a mass associated with them are apt to manifest themselves in the week or ten days prior to the menstrual period, and then diminish considerably with the onset of the period. She was examined, and nothing was found in the breast. Presumably, a thorough search was made because she had symptoms directing attention to that area. It does not say whether the examining physician elicited any tenderness in that part of the breast, but it seems very likely since that was the area in which she complained of pain. However, the record says that during examination no mass was observed.

Now we come to the brief physical examination that described the mass, but descriptions of masses made by someone else are rarely satisfactory. I suppose nowhere is it more necessary to have one's own hand conduct an examination and then interpret the findings than in the examination of an ambiguous lump. It was well enough defined so that a guess about the measurements could be hazarded. She had an area of induration presumably in the same area where she had discomfort. The location in the outer upper quadrant is significant, since that is where patients more often have painful nodularity or the manifestation of sclerosing adenosis or cystic mastitis. That is the usual site, because that quadrant is the one that contains the largest amount of breast tissue. Nothing is said about the axilla, and we might assume that the axilla showed no metastases. That is as far as I can go on that. The rest is pure conjecture. All I can say is that we have, I think, very wisely adopted the attitude that every lump in the breast may be a cancer and that the only safe assumption is that it is a cancer until the pathologist says it is not. The general policy we have in relation to breast tumors in this hospital, and again I say it is a wise one, is that all such lumps are to be subject to exploration without undue delay. It used to be said that there is no good Indian but a dead Indian. We could modify this and say the only place for a lump in the breast is in a bottle in the pathology laboratory. As long as a woman is harboring or may be harboring a cancer, immediate operation is warranted. Also, of the major cancers that affect mankind, cancer of the breast, if caught at an early stage, offers one of the most favorable prognoses of any type of malignant neoplasm. Therefore, if I were seeing this patient, I would say, "I cannot tell you what it is. It does not matter what I think it is. The important thing is that it is possible it may be cancer. Therefore, you should submit to exploration without delay and I will put it up to a pathologist. If it is not cancer, if it is benign, you will have the peace of mind that comes from the knowledge that it is benign. You will not be subjected to undue mutilation. [It would be harder to convince this patient on that point, because of the experience of the previous simple exploration with its unfortunate results.] You will be able to resume your usual activities in at least a week, if not sooner, and you will go on your way rejoicing that you do not have cancer."

If I were further pressed by this particular patient, or a member of the family, I would say: "No, I do not think we are dealing with cancer in this case." Why? Because none of the positive evidence of cancer or the presumptive physical evidence was present. Here is a mass that had developed rapidly from being not observed at all to being 2 or 3 cm. in size. It was first manifested by pain. There was no adherence and no distortion — only an area of induration described as an area of thickening. Again, one would want to feel it with one's own fingers to interpret it, but to me it is just a thickness that is not characteristic of cancer. In view of the fact that she had previously had sclerosing adenosis and mastitis in the opposite breast, I should think that this was a further manifestation of the same disease, which is of obscure etiology. Whether Dr. Nathanson will relate it to hormonal disturbances, whether it was of vascular origin or on what basis it originated, I am unable to say. But, I think it is going to be again the same thing that was found in the opposite breast.

DR. TRACY B. MALLORY: Dr. Bartlett, will you describe your findings?

DR. MARSHALL K. BARTLETT: Naturally, it was very distressing to have this patient come back after operation with a residual mass in her breast. Because we had a pathological report of a benign lesion, it seemed safe to experiment a little with hormonal therapy, but it failed to produce any significant change in the lesion. During this period the patient and her family were not happy about the situation and presently sought the opinion of another surgeon. He observed it for a time and then finding a bluish discoloration of the skin, he aspirated it, and got some blood out of it that led him to the conclusion that probably it was an old

hematoma, and as related in the record, she was admitted for evacuation of the hematoma. At that time, the bleeding encountered was so massive that operation was limited to biopsy of the tissue. As a result of the report of that biopsy, the patient was seen by several consultants and, on their advice, I finally did a radical mastectomy on her. Her convalescence was uneventful, and she was well for several months, as you have been told. She finally came back complaining of the other breast in which I could find no lesion, but for obvious reasons I suggested re-examination in a few weeks. At that time there was a mass. This mass was then excised, and immediate pathological examination made. There was no evidence of carcinoma. However, when the final sections came through an opinion was expressed that led to a radical mastectomy on the opposite side.

Clinical Diagnosis

Chronic cystic mastitis.

Dr. Taylor's Diagnoses

Sclerosing adenosis of breast.
Periductal mastitis.

Anatomical Diagnosis

Hemangiosarcoma of breast.

Pathological Discussion

Dr. Mallory: This case represents complete failure on the part of the Department of Pathology, and of me personally, to detect a malignant lesion of the breast. When Dr. Bartlett explored the first lesion in the left breast, I was present at the operation, and the tissue seemed so obviously benign that I did not consider it necessary to do a frozen section. We then put through a paraffin section and did find, as reported, adenosis.

At the time of the recurrence and the second biopsy, it became obvious that there was a malignant tumor, of endothelial origin, present in the breast.

Dr. Joseph C. Aub: Which breast?

Dr. Mallory: The left breast. It was a hemangioma growing with rapidity, so that we had to classify it as a hemangiosarcoma. At that time the radical mastectomy was done. The subsequent recurrence in the second breast was identical. Again, the biopsy looked perfectly benign grossly but on microscopical examination had the same type of malignant vascular tumor in it. When the recurrence appeared in the first breast, we went back to the original biopsy and found in one corner of one of our slides a little area, which had we paid attention to it, we should have recognized certainly as a hemangioma, if not as a malignant one.

Dr. Richard H. Wallace: Was the axilla involved on either side?

Dr. Mallory: No, there was considerable question on both occasions whether or not radical mastectomy should be done. Very often these hemangiomas do invade the pectoral muscles. It was believed that if one was going to remove the pectoral muscles it did not add much to the operation to dissect the axilla.

Have you any comment, Dr. Taylor?

Dr. Taylor: No, except that I am pleased to take a nose dive in such good company.

A Physician: How long has it been since operation?

Dr. Bartlett: About a year. The patient is all right at the present time.

Dr. Taylor: Was the second tumor an independent primary tumor or a metastasis?

Dr. Mallory: I believe it was independent. It was in the other breast, and on the far side. If the recurrence had been close to the line of the original incision, one would think otherwise.

Dr. Ira T. Nathanson: I saw this patient with Dr. Bartlett. The lesion in the right breast was a ringer for sclerosing or blunt duct adenosis. We could not make a diagnosis of hemangiosarcoma although we entertained it in view of the findings in the left breast. Consequently, we decided to explore the area in order to establish the diagnosis.

The various types of sarcomas of the breast rarely metastasize to lymph nodes but usually spread through the blood stream, commonly to the lungs. Hence, simple mastectomy has been ordinarily considered adequate to control the local disease. However, sarcomas of the breast, particularly of hemangiomatous origin, may invade the pectoral muscles. This was seen on the left side, where radical mastectomy was performed for this type of invasion. Similarly, it was our opinion that radical mastectomy on the right side was also the procedure of choice in this patient, who was in excellent physical condition. It was considered that the slight additional risk was minor in comparison with the possibility of leaving residual disease in the muscle if simple mastectomy was elected.

References

1. Foote, F. W., and Stewart, F. W. Comparative studies of cancerous versus noncancerous breasts. *Ann. Surg.* **121**:6 and 197, 1945.
2. Warren, S. Relation of "chronic mastitis" to carcinoma of breast. *Surg., Gynec. & Obst.* **71**:257-373, 1940.

CASE 35322

Presentation of Case

A twenty-four-year-old married woman entered the hospital because of morning hemoptysis.

The patient had been well until shortly after a pregnancy and delivery under ether anesthesia eight months before admission, when she developed a chronic cough, particularly in the morning, productive of a tablespoonful of whitish-yellow, non-

foul sputum. This persisted and in the three months before entry became associated with a dull, aching and occasionally sharp twinge of right subscapular pain on coughing. The patient denied chills, fever, night sweats and other constitutional symptoms, but noted progressive fatigability and a 15-pound weight loss despite a good appetite. The fingernails seemed to change during this period from normal configuration to a clubbed appearance. Three weeks before entry the patient had the onset of morning hemoptysis from a teaspoonful of bright-red blood to bloody streaking of the sputum. This was a daily occurrence but was unassociated with new symptoms or change in other symptoms. Five years before admission the patient developed a firm, nontender, and otherwise asymptomatic mass in the right anterior cervical region, which was removed in another hospital and allegedly found to contain a "pocket of pus." About two years before admission she noted the gradual recurrence of a mass in the same region, with some increase in size up to the present.

The family and past histories were not remarkable. The patient denied known contact with tuberculosis.

Physical examination revealed a slender, well developed woman in no discomfort. There were several firm, nontender, freely movable, nodular masses in the right anterior cervical triangle — one measuring 2 by 3 cm., with adjacent 0.5-cm. nodules on the sternomastoid muscle, and one measuring 2 by 5 cm. in the supraclavicular fossa, which seemed to descend into the upper mediastinum. No other significant lymphadenopathy or abnormal masses were noted except for a slightly tender, freely movable mass, 2 by 5 cm., in the right breast and a similar mass, 2 by 3 cm., in the left breast. Early clubbing was noted in all fingernails. Examination of the chest revealed signs consistent with consolidation in the right upper lobe, most marked anteriorly. There were a Grade I short, blowing, basal systolic murmur and a split second sound at the base. The remainder of the physical examination was not remarkable.

The temperature was 98.6°F., the pulse 100, and the respirations 20. The blood pressure was 125 systolic, 70 diastolic.

Examination of the blood disclosed a white-cell count of 14,000, with 92 per cent neutrophils. The hemoglobin was 11 gm. per 100 cc. Urinalysis revealed a + test for albumin and was otherwise negative. Sputum examination for acid-fast bacilli was negative. A skin tuberculin test was negative in dilutions of 1:100,000 and 1:10,000.

X-ray study of the chest revealed increased density in the anterior segment of the right upper lobe, with some degree of collapse and honeycombing in the lower portion of the lobe, interpreted as dilated bronchi. There was increased prominence of the right hilus, and some calcification was demonstrated in the right lung. The left lung was normal. The findings were interpreted as "drowned" lung, secondary to obstruction in the right-main-stem bronchus.

On the fourth hospital day an operation was performed.

Differential Diagnosis

Dr. John G. Scannell: In second-year medical school we were asked in an examination to enumerate and discuss the causes of hemoptysis and were expected to rattle off with a fair degree of assurance the fourteen (or was it seventeen?) diseases concerned. I wish I could muster the same assurance today. However, assuming that the hemoptysis was bona fide, and in the present case there is every reason to believe that it was, we must look to the bronchial tree for either a primary lesion or changes secondary to pulmonary hypertension. With no evidence for the latter, I think we can safely dismiss it and confine our attention to diseases that give rise to localized changes in the lungs, to a definite lymphadenopathy and to generalized systemic changes — namely, weight loss, chronic fatigue and clubbing. As a point of departure, may we see the x-ray films?

Dr. James C. McCort: The examination of the chest reveals an increase in density of the anterior and apical segments of the right upper lobe. These segments are reduced in size. Within the involved segments there are radiolucent areas giving the segments a honeycombed appearance. This may be due to dilated bronchi and bronchioles. None of these radiolucent areas show a fluid level. There is a slight amount of fluid in the overlying pleura and in the minor fissure on the right side. The right-upper-lobe bronchus can be traced for a distance of 1 cm. distal to its orifice, at which point it is narrowed and apparently blocked. There is no definite evidence of displacement of the trachea or mediastinum. Enlargement of the right peribronchial lymph nodes is present. There are also a few flecks of calcification in the peribronchial area, which may be within lymph nodes. The remaining lung fields are clear. The diaphragm is in its normal position. There is no blunting of either costophrenic sinus. The heart and vessels appear normal.

Dr. Scannell: Are you impressed by the curving deviation of the trachea to the left? I assume that is compatible with the large lymph node in the right cervical triangle described in the physical examination.

Dr. McCort: The cervical portion of the trachea does show a slight displacement to the left side, which may be due to the mass described in the right side of the neck. The exact amount of displacement is difficult to determine because there is slight scoliosis of the spine.

Dr. Scannell: We have, therefore, evidence of a lesion that involved bronchi of the order of

segmental bronchi, and hence presumably could be visualized and, perhaps, biopsied through a bronchoscope. There were also cervical lymph nodes that, according to the description given, were sufficiently abnormal to warrant biopsy. We are, however, called upon to make a diagnosis in advance of these diagnostic maneuvers.

In a patient of another sex and another age group, the diagnosis would be carcinoma until proved otherwise. The marked male-sex preference of bronchiogenic carcinoma is well known (usually estimated to be about ten to one), and in a patient in the twenties the unlikelihood of carcinoma is greatly increased. Except for these facts, however, the history of an unfamiliar cough, dull, aching chest pain, weight loss, chronic fatigue and, especially, early pulmonary osteoarthropathy are all highly suggestive, and the finding of a segmental lesion by x-ray examination and enlarged cervical, paratracheal and mediastinal lymph nodes is almost confirmatory. To rule out cancer requires a positive diagnosis of something else, presumably benign tumor, a chronic suppurative process or tuberculosis.

We might mention other rare tumors, notably chorionepithelioma and lymphoma. The former is, perhaps, suggested by the onset following pregnancy, but that is all that we have in its favor and I shall discard it. Lymphoma of the lung is rare, particularly with endobronchial involvement, but it is known to occur; it may invade the bronchial tree, and certainly is suggested here in view of the rather striking cervical-lymph-node involvement and the evidence of considerable hilar lymphadenopathy by x-ray examination. In addition, we have the evidence of a chronic disease without great blood loss. I am a little disturbed by the apparent lack of fever.

In the case of lymphoma of the lung reported from this hospital by Dr. Churchill[1] in 1947, there were several points of similarity to the present case. The patient was a woman, she complained of a dull aching pain beneath the right scapula, and her physical signs were those of consolidation — that is, an open lobar bronchus with solidified lung adjacent to it. On the other hand, she had no lymph-node involvement, no clubbing, no hemoptysis and no anemia. She had had symptoms some six months or so, with episodes of fever. However, the case presented apparently a solitary lymphoma of the lung itself, and not, as we must postulate in the case under discussion, a lymphoma situated in the right bronchial node and invading and involving the right-upper-lobe bronchi secondarily. Certainly, the cervical lymph nodes suggest lymphoma in that they were freely movable, firm, nontender and of considerable size. Were they of tuberculous origin, I would expect them to be less discrete, more uniformly involved and possibly displaying some calcification on x-ray study. Furthermore, a definite diagnosis of tuberculosis was ruled out by negative sputums and negative tuberculin tests. An acid-fast node eroding into a bronchus is, in a way, an attractive diagnosis to make for this patient, but I do not see how we can support it.

Of the possibilities outlined above, benign tumor was mentioned. The patient was a woman, she was young, she had had some bleeding, and she had segmental secondary changes. However, this diagnosis fails to account for the enlarged lymph nodes, except the very rare bronchial adenoma with extensive satellite-lymph-node involvement. In any case, were the latter involved secondary to a pulmonary lesion, I would expect greater involvement of the subcarinal node, and as we can see by the overexposed film of the chest, the carina is quite sharp and normal in appearance. Incidentally, were the lesion a highly undifferentiated bronchiogenic carcinoma of the oat-cell variety, I should expect the same distortion of the carina as is present in this case.

Turning to a more hopeful diagnosis, in view of the onset of cough following an inhalation anesthesia, chronic lung abscess must be carefully considered. Chronic, somewhat productive cough, hemoptysis and clubbing are in its favor. Absence of fever, the presence of cervical lymph nodes and the location in the anterior and apical segments of the upper lobe as opposed to the posterior segment of that same lobe are against it. Both by history and on x-ray study there was no evidence of a sequestration of lung tissue. Furthermore, no penicillin or streptomycin had been given, which might obscure the natural history of the disease.

Bronchiectasis limited to the right upper lobe is a possibility, but here again the history is relatively short and atypical, the x-ray picture, in spite of the suggestion of dilated bronchi, is not that of saccular, dry bronchiectasis in this area, and the cervical lymph nodes are not accounted for. Bronchiectasis secondary to a foreign body is always a possibility, especially in view of the previous anesthesia, but we have no evidence on which to base this diagnosis.

A closely related lesion — namely, chronic nonspecific pneumonitis of the cholesterol type[2] — certainly merits our consideration. The history is not at all out of line, although one would expect more evidence of an active inflammatory process at some time in its development and less striking hemoptysis, and although marked regional lymphatic involvement is the rule (and is evident here on the chest film), again the presence of these definitely abnormal cervical lymph nodes is difficult to explain. Strangely enough, at no time was viral pneumonia diagnosed and antibiotics given.

One always wonders, particularly in this hospital, about the diagnosis of sarcoid in puzzling lymphatic and pulmonary lesions, but if I understand Dr. Freiman[3] aright, even considerable enlargement

of the hilar lymph nodes is rarely associated with pressure or obstructive phenomena, a point of differentiation from lymphoma or carcinoma.

Metastatic carcinoma is also a definite possibility, and in this case would incriminate the thyroid gland or some silent primary focus. We have little evidence to single out the former, and no real evidence to indicate the latter — for example, a silent hypernephroma. At some risk, I am going to disregard the bilateral breast masses.

Clearly, a most helpful next step in the diagnosis would be either a bronchoscopic biopsy or a cervical-lymph-node biopsy, and one of these, I suspect, was the operation performed on the fourth hospital day. When I embarked upon this discussion, I was inclined toward a nonspecific chronic pneumonitis with marked hilar involvement, believing that the history, the age and sex of the patient, the x-ray picture and the physical signs were consistent with this diagnosis, but as I reconsider it, I am more than ever impressed by the cervical lymphadenopathy and therefore elect lymphoma with bronchial encroachment and erosion as the probable diagnosis.

Clinical Diagnosis

Malignant lymphoma.

Dr. Scannell's Diagnosis

Malignant lymphoma.

Anatomical Diagnosis

Malignant lymphoma, Hodgkin's type.

Pathological Discussion

Dr. Benjamin Castleman: On the ward, the differential diagnosis rested mainly between tuberculosis and lymphoma. Dr. Joseph C. Aub, who was on service at that time, believed that "the most reasonable single diagnosis is lymphoma occluding the bronchus."

One of the cervical lymph nodes was removed, and it showed the characteristic microscopical findings of Hodgkin's disease. Dr. Benedict reported that bronchoscopy of the right bronchial tree was difficult because of the apparent pressure on it from the right side, but with the right-angle telescope, the orifice of the upper lobe was readily visible and found to be markedly stenotic. No outcropping could be seen.

The patient was then given x-ray treatment over a period of eight days, 300 r per day, the anterior and posterior right upper mediastinum each receiving 900 r and the supraclavicular region 600 r.

The patient did not return to this hospital, but it was later learned that there was a good response to this treatment for about a year. She then entered another hospital very sick with fever, weight loss, anemia, pleural effusion and ascites. After tapping of the chest, a mass was observed within the right lung and after tapping of the abdomen, the liver and spleen were found to be enlarged. X-ray treatment was again given, but this time there was no improvement. However, a course of nitrogen mustard produced a miraculous change in the patient. The mass in the lung practically disappeared, and the patient was able to be herself again. This remission lasted for about three weeks, but she then returned with pain in the opposite chest. Nitrogen mustard again brought relief. She has just recently been discharged from the hospital after her third remission, which is about two years since admission to this hospital.

References

1. Churchill, E. D. Malignant lymphoma of lung and pulmonary coccidioidomycosis: clinic on surgical lesions of lung with consolidation. *S. Clin. North America* 27:1113-1120, 1947.
2. Waddell, W. R., Sniffen, R. C., and Sweet, R. H. Chronic interstitial pneumonitis: report of 10 cases showing chronic interstitial pneumonitis and unusual deposits of cholesterol. *J. Thoracic Surg.* (in press).
3. Freiman, D. G. Sarcoidosis. *New Eng. J. Med.* 239:664-671, 709-716 and 743-749, 1948.

The New England
Journal of Medicine

Formerly
The Boston Medical and Surgical Journal
Established 1828

Official Organ of
The Massachusetts Medical Society
and
The New Hampshire Medical Society
Owned by the Massachusetts Medical Society and Published Weekly under the Jurisdiction of the Committee on Publications

Richard M. Smith, M.D., *Chairman*
James P. O'Hare, M.D. Conrad Wesselhoeft, M.D.
Oliver Cope, M.D. John Fallon, M.D.

Joseph Garland, M.D., Editor

Associate Editors
Thomas H. Lanman, M.D. Donald Munro, M.D.
Henry Jackson, Jr., M.D.

Clara D. Davies, Executive Editor
Robert O'Leary, Assistant Editor

Editorial Board
C. Guy Lane, M.D. Maxwell Finland, M.D.
Henry R. Viets, M.D. Carroll B. Larson, M.D.
Robert M. Green, M.D. C. Stuart Welch, M.D.
Dwight O'Hara, M.D. Vernon P. Williams, M.D.
Fletcher H. Colby, M.D. Benjamin Castleman, M.D.
Robert L. Goodale, M.D. Hugh R. Leavell, M.D.
Chester M. Jones, M.D. J. Englebert Dunphy, M.D.
Harvey R. Morrison, M.D. Charles H. Burnett, M.D.

Subscription Terms: $7.00 per year in advance, postage paid, for the United States (medical students, $4.00 per year); Canada, $8.00 per year (Boston funds); $9.50 per year for all foreign countries belonging to the Postal Union.

Material should be received not later than noon on Thursday, three weeks before date of publication.

The Journal does not hold itself responsible for statements made by any contributor.

Communications should be addressed to the *New England Journal of Medicine*, 8 Fenway, Boston 15, Massachusetts. Telephone KE 6-2094.

EDUCATION OF THE FAMILY PHYSICIAN

Of all the manifold problems besetting the medical profession today in its desire to provide the public with the best medical care, that of restoring the family physician to a position commensurate with his contribution to society, by improving standards of general practice, appears to be one of the most pressing.

The pattern of practice is obviously changing, and the next few years will undoubtedly bring profound alterations in the organization for the provision and distribution of medical care, as well as in the methods of paying for it. Nevertheless, there can be no change in what is fundamental to the best medical practice — namely, a solid foundation of well trained family physicians. True, the public has strayed away from reliance on the family doctor, owing largely to overemphasis of specialization, so highly developed and widely touted in all phases of American life, but there seems now to be a trend back to him, with a beginning awareness of the proper relation between the general physician, as the first echelon, and the specialist, whom he will call when needed. Not the least of the influences in this change may be certain types of group practice in which several general practitioners or family physicians work on an equal footing with various specialists to whom they refer patients as indicated. Regardless of whether group medicine is to become the accepted pattern and whether prepayment insurance becomes the solution for the economic difficulties, nothing will succeed in replacing the family physician as the most important cog in the whole system.

Actually, the profession itself is largely responsible for the devaluation of the family doctor. Clinical teaching in the medical schools is largely provided by specialists, and postgraduate education of interns and residents in teaching hospitals is chiefly carried out by specialists and research workers. The house staff tends to believe that going into practice is a less worthy career than one devoted to teaching and research — a step downward, rather than merely a parallel road. The family physician who refers problem cases to these hospitals is often looked down upon by the house staff, and referred to patronizingly as the "L.M.D." Perhaps teaching hospitals should arrange for qualified general practitioners to enter into certain phases of teaching. The family doctor is likewise to blame by trying to do too much and becoming so busy he cannot keep up with attendance at meetings or with the medical literature. Instead he would do well to put such educational activities on a required list each week. Too often he has had insufficient hospital training, and the opportunities for good training for this type of work are too few and poorly organized.

The economics of medicine adds to the process of his devaluation. Although he must combine the skills of diagnostician, therapist for at least 75 per cent of the problems confronting him, adviser for family and individual social problems, and public-health adviser, for all these diffuse but vital functions he is undercompensated in comparison with many specialists.

Finally, there appears little doubt that the process of board certification has gone too far, par-

ticularly in internal medicine. Certainly, a great many certified "internists" are, actually, family physicians. Yet the prize of a certificate by the Board of Internal Medicine is such that men planning to devote themselves to medicine rather than to surgery or other specialties requiring technical skills are often motivated in planning their hospital training by getting so many years of credit — putting in time, so to speak — rather than by an intrinsic desire for postgraduate study per se. Too little consideration is given to the fact that medical education is a lifelong process, and even though a man goes into practice he must continue to develop himself educationally in the wards and at conferences of the hospital of his community. Although two years of internship training should be a minimum for the family physician it might be very desirable to revive the old apprentice system whereby the young physician works for a year under the supervision of an older staff member of a community hospital. If this could be effectively carried out, it would probably be more valuable than an additional hospital residency.

Recently the Council on Medical Education and Hospitals of the American Medical Association has included a residency in general practice in its "Essentials of Approved Residencies and Fellowships." This residency is designed to attract men who wish to become family physicians, and is not conceived with the thought that specialty boards will accept it as meeting in part their training requirements. This and other movements are in line with the trend toward elevating standards of general practice as required by modern life, and in elevating the position of the modern family physician. In Boston the Faulkner Hospital has announced a new internship of two years, designed to provide optimum training in this field. Emphasis is placed on internal medicine, to which twelve months are devoted, with another year divided among pediatrics, obstetrics and surgery. A period devoted to medicine and pediatrics is to be spent at a larger teaching hospital in affiliation. The internship is announced as being especially designed for men who wish to become family physicians.

Such programs should go far toward improving the level of general practice and should result in attracting more and better men into this field. Perhaps one of the most important factors in combating the demand for compulsory health insurance will be the development of many well trained family physicians, with a better sense of proportion, both within the profession and on the part of the public, concerning specialization.

"WHAT IS A MAN PROFITED?"

HOFFMAN, elsewhere in this issue of the *Journal*, considers the clinical results of leukotomy in 42 patients treated by psychosurgery at the Veterans Administration Hospital in Bedford, Massachusetts. The study covers the years 1947 and 1948. All but one of the patients were schizophrenics whose illness and hospitalization had been of two to twenty years' duration. Results at the time of the study showed 4 patients to be dead; 14 out of the hospital, either discharged or on trial visits; 16 still in the hospital but so improved that they could have been living at home; and 8 still in the hospital and requiring hospital care because of continued disturbed behavior.

These results are comparable to those more recently released by the Yale University News Bureau on the Connecticut Co-operative Lobotomy Study, a joint project of the Department of Psychiatry and Mental Hygiene of the Yale University School of Medicine and the three state mental hospitals of Connecticut. This study, organized in 1946, reports on 294 postoperative patients, mostly severe cases of schizophrenia, who had been hospitalized for an average of five years prior to operation.

According to this report 36 per cent of the patients were able to return to their homes within a year after operation, and a total of 61 per cent had shown definite improvement in their mental health. An important measure of their status is their capacity for work. Of the 294 patients less than 7.5 per cent were capable of work before their operation. After the lobotomy more than 25 per cent were working full time, and an additional 38 per cent were employed on a part-time basis.

So far as objective behavior is concerned, impulsive, overactive and aggressive traits, suicidal attempts and constant refusal of food had disappeared in over three fourths of the group. Subjectively, more than 85 per cent of the patients had lost such disturbing symptoms as depression, obsessive-compulsive behavior and anxiety.

These figures are certainly encouragingly in favor of the operation, but Hoffman presents also the

other side of the argument, considering his cases from the point of view of qualitative results. The behavior and frequently the comfort of the patients is admittedly improved, but it is by the process of subtraction, he implies, and never by addition.

The tendency, he points out, is to overlook "the very real and permanent losses to the integrity of the personality" sustained as a result of operation. In the removal of the disease focus an uncertain quantity of vital tissue indispensable in making up the total personality of the patient is also removed. Even in consideration of a certain general vagueness concerning just what constitutes a soul, some observers have described post-lobotomy patients as persons who had lost this ill defined but apparently indispensable part of their individuality. Perhaps it would be more acceptable to say that many of them had lost the vital spark of their personality, or the particular spiritual value compounded of the emotions and the reason, and consisting of the ability to know sorrow and happiness, peace and anxiety, compassion and understanding that puts the final touches on the human being.

Psychosurgery is one of the fruitful experiments that medical science has occasionally to offer, but its subjects must still be selected with the utmost care. Perhaps, as Greenblatt and Myerson* suggest, the refinements of topectomy will avoid some of the disadvantages of lobotomy.

*Greenblatt, M., and Myers, P. G. Psychosurgery. *New Eng. J. Med.* 240:1006-1017, 1949.

SOLOMON'S KITCHEN

KING SOLOMON, it is said, on a visit to Hebron, found the people of the district so poor and yet so loyal that he established a fund to provide them with daily food "until the end of the world." Presumably Solomon's fund has been exhausted, but so strong is tradition that the custom has been maintained even to the present time.

Last December, however, the continuity of the practice established by the wise king was at last about to be broken. The cupboard was bare. Then on Christmas eve trucks of the United Nations International Children's Emergency Fund rolled into the area.

A million refugees, *UNICEF News* reports, are waiting out their destiny in the desert about Israel. Food and shelter are their first problem; idleness comes next. Schools have been started for the children, but there are no fields for the men to till; no wool for the women to weave. UNICEF is now able to bring some measure of relief to the half million children and pregnant and nursing women among these refugees — a relief, purchased out of the allocation of $6,411,000 made to the area by the executive board, that comes from all over the world.

The United States, Canada and Denmark have sent milk; cod-liver oil has come from Iceland, and margarine from Australia and Belgium. Meat, wheat and flour have come also from Australia, and wheat and flour from Ethiopia; dried fruit has been sent from South Africa and Yugoslavia, rice from the Dominican Republic, Italy and Siam, and soap from New Zealand.

Palestine is but one of the areas where the world's present misery makes such aid as that furnished by UNICEF imperative. In the first year of the program's operation 84,000,000 supplementary meals were provided in Austria. Shoes and blankets are now being distributed in Bulgaria. Czechoslovakia, a donor as well as a recipient country, has received over $3,000,000 in supplies, with the government contributing $1,000,000 and the people having raised an additional $300,000.

In Greece 670,000 children and women, of whom 250,000 are refugees, receive supplementary meals; over a million Italian children are fed daily. Meals are provided in Yugoslavia; a BCG antituberculosis vaccination program is under way in Morocco; health workers are being trained in China. Danish teams of BCG vaccinators are at work in India, and a UNICEF Medical Mission is operating in Pakistan. Children are being fed in the Philippines.

The small countries, it is interesting to note, are leading in the response to the United Nations appeal for children, and of these Iceland, with a per capita contribution of $4, leads all the rest. Other material donations have come from Australia, New Zealand, South Africa, Canada, Mozambique. Czechoslovakia raised a total of $1,500,000, $300,000 of which was for UNICEF. Yugoslavia and Austria have made their contribution, and even Italy has raised a quarter of a million dollars.

If the strength of a nation, as has been written, lies in the hearts of its people, then the world may yet struggle through its present misery to a better way of life.

Such shocking exhibitions of dyed heads as are occasionally met with in the streets, in this change loving age, when fashionable people think they can color their skins and their hair with as much ease as politicians turn their coats under a new administration, show the necessity of a more perfect and expeditious mode of accomplishing the metamorphosis.

Boston M. & S. J., *August 8, 1849*

NOTES FROM THE MEDICAL EXAMINER

IDENTIFICATION OF BLOODSTAINS — II

The proof that a stain has been caused by blood is a significant step in its identification.[1] To show that it has been caused by human blood is of much greater importance.

Before the beginning of this century the characterization of the species origin of bloodstains was made solely on the basis of the morphology of the red cells. Although there are well recognized species differences in the size and shape of the intact mammalian erythrocyte, the effects of autolysis, hemolysis, drying and other mechanical distortion are such as to relegate this method of species identification to one of minor importance today.

In 1901 Uhlenhuth[2] introduced the immunologic tests for human blood. He showed that it was possible to prepare a specific antihuman rabbit serum by repeatedly injecting a rabbit with human blood. The rabbit serum, when layered with a dilute solution of human blood, caused a precipitate to form at the interface. The principle of this test forms the basis of present medicolegal tests for species identification of blood.

Uhlenhuth's initial experiment was simple and qualitative. It failed to reveal the fact that in many cases antiserums against the blood of a particular animal also show cross reactions with the blood of other animals. Thus, antihuman serum will probably react with the blood of monkeys and apes, and will occasionally react with the bloods of many other animals, even those remotely related. These cross reactions are dependent upon a number of factors, some of which are not understood. At present there is no certain method of preparing a high-titer specific antiserum by the use of a single animal. Some animals fail to produce strong antiserums; others produce antiserums that are nonspecific.

The specificity of an antiserum may be improved by absorption of the undesired antibodies.[3] If an antihuman serum is found to exhibit an undesired cross reaction with dog blood, it may be mixed with dilute dog blood, allowed to stand several hours and then centrifuged. The resulting serum will no longer react with dog blood, but will retain its antihuman properties. By such absorption it is likely that much of the "general animal" antibodies will be removed also, and that undesired cross reactions with any other animal bloods will be reduced greatly. In other words, nonspecific antibodies tend to be nonspecifically absorbed.

Because human blood is a complex mixture of proteins, antihuman-blood rabbit serum contains a mixture of antibodies. Some of these are capable of reacting with most of the soluble proteins of human origin, regardless of whether they are blood or not. Wiener[4] has suggested the use of antihuman hemoglobin serums instead. These may be prepared by injection of rabbits with washed, laked human erythrocytes. It is then possible to identify human blood in one simple test, without the necessity of preliminary chemical tests to establish the presence of hemoglobin. Hemoglobin is a poor antigen; with it the production of strong antiserums is difficult. However, the inconvenience in preparation of antihuman hemoglobin serum is outweighed by the advantages gained in its use.

Antihuman hemoglobin serums frequently show a cross reaction with human serum. The undesired antiserum factor may be removed conveniently by "in vivo" absorption within the rabbit. Hektoen and Welker[5] have shown that if multiple antigens are injected into an animal multiple antibodies are formed, and that each may be removed individually during the "negative phase" by an injection of its corresponding antigen. Accordingly, the antiserum factor of an antihemoglobin rabbit may be removed "in vivo" by injection of the animal with an appropriate amount of hemoglobin-free human serum. If the animal is bled during the "negative phase" of twelve to forty-eight hours thereafter, the rabbit serum will react with human hemoglobin, but not human serum.

It is frequently useful for medicolegal purposes to prepare a general-animal-blood antiserum. This is done by subjecting several rabbits to a series of injections of a mixture of bloods from many animals, exclusive of human beings. When the antibody titer has reached a satisfactory level, a single injection of human blood is administered, and the animals are bled during the "negative phase." The best antiserums are pooled. An unknown bloodstain is then tested against human hemoglobin rabbit serum and antianimal rabbit serum. If it reacts with the former and not the latter, the stain is of human blood, and if with the latter and not the former, it is of animal origin.

REFERENCES

1. Notes from the Medical Examiner. Identification of bloodstains — I. *New Eng. J. Med.* 241:78, 1949.
2. Uhlenhuth. Eine Methode zur Unterscheidung der verschiedenen Blutarten, im besonderen zum differentialdiagnostischen Nachweise des Menschenblutes. *Deutsche med. Wchnschr.* 27:82, 1901.
3. Landsteiner, K. *The Specificity of Serological Reactions.* 178 pp. Springfield, Ill.: Charles C Thomas, 1936.

4. Wiener, A. S. *Blood Groups and Transfusion.* Third edition. 438 pp. Springfield, Ill.: Charles C Thomas, 1943.
5. Hektoen, L., and Welker, W. H. Specificness of negative phase in precipitin production. *J. Infect. Dis.* 57:337-344, 1935.

JOSEPH T. WALKER, PH.D.
Chemist, Massachusetts Department of Public Safety, and *Associate in Legal Medicine*, Harvard Medical School.

MASSACHUSETTS DEPARTMENT OF PUBLIC HEALTH

PHYSICIANS' HANDBOOK ON BIRTH AND DEATH REGISTRATION

The Massachusetts Department of Public Health has arranged with Edward J. Cronin, secretary of the Commonwealth, to send copies of the tenth edition of the *Physicians' Handbook on Birth and Death Registration* to all practicing physicians and boards of health in Massachusetts. This handbook is valuable to physicians because it gives the important facts that physicians should know regarding registration requirements and procedures.

Additional copies can be obtained by application to the Secretary of State's office, State House, Boston 33, Massachusetts.

BOOKS RECEIVED

The receipt of the following books is acknowledged, and this listing must be regarded as a sufficient return for the courtesy of the sender. Books that appear to be of particular interest will be reviewed as space permits. Additional information in regard to all listed books will be gladly furnished on request.

Research Publications. Association for Research in Nervous and Mental Disease. Volume XXVII. *The Frontal Lobes: Proceedings of the Association, December 12 and 13, 1947, New York.* 8°, cloth, 901 pp., with 237 illustrations. Baltimore: Williams and Wilkins Company, 1948. $12.50.

Fifteen years ago the Association published its volume on the localization of function in the cerebral cortex. The present volume deals with the frontal lobes and the material is divided into four parts: biology, experimental studies, clinical studies and frontal lobotomy. There are twenty-seven articles in this volume of the Research Publications, twenty-one of which are now out of print and unobtainable from the publishers or the Association. The series is very valuable and should be in all medical libraries. The present volume should be available to all neurologists and psychiatrists.

Industrial Hygiene and Toxicology. Volume I. Frank A. Patty, editor. 8°, cloth, 531 pp., with illustrations and tables. New York: Interscience Publishers, Incorporated, 1948. $10.00.

This volume is the first of a set of two projected volumes. Eleven specialists have contributed to this part, which is devoted to the various aspects of industrial hygiene. Some of the topics include personal and environmental factors in fatigue and competence, physiologic effects of abnormal atmospheric pressure, the mode of entry and action of toxic materials, sampling and analysis of atmospheric contaminants, radiant energy and radium (including poisoning by radium and thorium), ventilation, occupational dermatoses, the visible marks of occupation and occupational diseases, fire and explosion hazards of combustible gases, vapors and dusts, respirators and respiratory protective devices and dust and its role in occupational diseases. The literature noted is printed as footnotes on the pertinent pages. There is an extensive index of subjects. The type, printing and paper are excellent. Although this volume is large, it weighs only 3 pounds. Volume II, to be published later, will be devoted to various toxic compounds. The set is recommended for all medical, public-health and industrial-plant libraries.

NOTICES

ANNOUNCEMENT

Dr. Elmore M. Campbell announces the opening of an office for the practice of medicine at 187 East Cottage Street, Dorchester.

NATIONAL GASTROENTEROLOGICAL ASSOCIATION

The National Gastroenterological Association will hold its fourteenth scientific session at the Hotel Somerset in Boston, on October 24-26, 1949.

Among the outstanding speakers to present papers at the convention will be Dr. Owen H. Wangensteen, professor of surgery, University of Minnesota Medical School; Dr. Frank H. Lahey, Dr. William B. Castle, and Dr. Maxwell Finland, of Boston; Dr. George Crile, Jr., Cleveland, Ohio; Dr. J. M. T. Finney, Jr., Baltimore, Maryland; and Lord Alfred Webb-Johnson, president of the Royal College of Surgeons, London, England, who will be a guest of honor at the banquet to be held on Tuesday evening, October 25.

At the annual banquet to be held at the Somerset, the winner of the National Gastroenterological Association's 1949 prize award contest for the best unpublished contribution on gastroenterology or an allied subject, will receive the prize of $100 and a certificate of merit.

Immediately following the convention on October 27-29, 1949, the Association is sponsoring a course in gastrointestinal surgery at the Boston City Hospital.

Further information concerning the program and details of the course may be obtained by writing to the secretary, National Gastroenterological Association, 1819 Broadway, New York 23, N. Y.

AMERICAN PUBLIC HEALTH ASSOCIATION

The annual meeting of the American Public Health Association and related organizations will be held in New York City from October 24 to 28, with joint headquarters at the Hotel Statler and Hotel New Yorker. At the two general sessions of the Association the Lasker Awards for 1949 and the Sedgwick Memorial Medal will be presented, and the address of the president, Dr. Charles F. Wilinsky, of Boston, will be read.

Details regarding the program may be obtained from Dr. Reginald M. Atwater, Executive Secretary, American Public Health Association, 1790 Broadway, New York City.

AMERICAN ACADEMY OF PEDIATRICS

The American Academy of Pediatrics will hold its annual meeting in San Francisco, California, at the Palace Hotel, November 14 to 17, 1949.

PAN-AMERICAN CONGRESS OF PEDIATRICS

The second Pan-American Congress of Pediatrics (Tenth District of American Academy of Pediatrics) will be held in Mexico City, at the Del Prado Hotel, from November 2 to 5. The third National Congress of Pediatrics of the Mexican Society of Pediatrics will be held in Mexico City from October 30 to November 10.

INTERNATIONAL COLLEGE OF SURGEONS

The annual assembly and convocation of the International College of Surgeons, United States Chapter, will be held in Convention Hall, Atlantic City, from November 7 to 12.

The program will include scientific sessions on general surgery; eye, ear, nose and throat surgery; gynecology and obstetrics; urology; and orthopedic, thoracic, plastic and neurologic surgery. Special surgical clinics will be held in Philadelphia hospitals on November 7.

All doctors of medicine interested in surgery are invited. Further information regarding the program may be obtained from Dr. Arnold S. Jackson, secretary of the Chapter, at the Jackson Clinic, Madison 4, Wisconsin. Hotel reservations may be made with E. D. Parrish, Haddon Hall, Atlantic City, New Jersey.

AMERICAN ACADEMY OF GENERAL PRACTICE

The American Academy of General Practice will hold its second Scientific Assembly in St. Louis, Missouri, on February 20-23, 1950. Further information may be obtained by writing Mr. Mac F. Cahal, Executive Secretary, 406 West Thirty-Fourth Street, Kansas City 2, Missouri.

GRANTS AND FELLOWSHIPS IN CANCER RESEARCH

The Committee on Growth of the National Research Council, acting for the American Cancer Society, is accepting applications for grants and fellowships. Applications for new grants in cancer research will be received until October 1. Investigators now receiving grants will be notified individually regarding application for the extension of these grants. Final decision on applications will be made in most cases soon after February 1, 1950. Grants approved at this time ordinarily will become effective July 1, 1950.

Fellowship applications may be submitted at any time. Those received prior to November 1 will be acted upon by the Committee on Growth in December. Those received between November 1 and March 1 will be acted upon in April. Fellowships ordinarily will begin July 1, though this date may be varied at the request of the applicant.

During the past year the American Cancer Society, Inc., on recommendation of the Committee on Growth, has approved research grants and fellowships totaling over $2,000,000.

Communications regarding grants and fellowships should be addressed to Executive Secretary, Committee on Growth, National Research Council, 2101 Constitution Avenue, N. W., Washington 25, D. C.

SHORT-TERM DUTY AVAILABLE FOR ARMY MEDICAL RESERVISTS

The Department of the Army has recently published Special Regulation 140-210-10, which authorizes commanders of Army installations to place volunteer reserve officers of the Medical, Dental, and Veterinary Corps on active duty for periods of from 1 to 29 days a month, but not more than 90 days of active duty in a fiscal year. Officers selected will be placed on active duty in the grade in which currently commissioned in the Officers' Reserve Corps.

Active duty will be performed at an Army installation or activity situated within the vicinity of the officer's home. No officer will be ordered to active duty where travel to duty station is involved. However, authorization whereby officers may volunteer as ship's surgeon on an Army transport for a round-trip voyage is given in the regulations.

ASSOCIATION OF SCHOOL PHYSICIANS

The interim committee appointed at the Amherst meeting convened at Hotel Sheraton, Worcester, on July 24. School physicians should watch these columns and those of the *Newsletter* of the Massachusetts Department of Public Health for notices and announcements.

ALVARENGA PRIZE

On July 14, 1949, the College of Physicians of Philadelphia awarded the Alvarenga Prize for 1949 to Owen Harding Wangensteen, M.D., Ph.D., professor of surgery, University of Minnesota, for his contributions to the etiology and therapy of gastric and duodenal ulcer. Dr. Wangensteen will deliver the Alvarenga Lecture on this subject at the College of Physicians of Philadelphia on November 2.

The Alvarenga Prize was established by the will of Pedro Francisco da Costa Alvarenga, of Lisbon, Portugal, an associate fellow of the College of Physicians of Philadelphia, to be awarded annually by the College of Physicians on the anniversary of the death of the testator, July 14, 1883.

SOCIETY MEETINGS AND CONFERENCES

SEPTEMBER 6-10. American Congress of Physical Medicine. Page xiii, issue of March 24.

SEPTEMBER 8. Care of the Terminal Stage of Cancer. Dr. John W. Spellman. Pentucket Association of Physicians. 8:30 p.m. Haverhill.

SEPTEMBER 28. New England Pediatric Society. Page 136, issue of July 21.

SEPTEMBER 28-30. Mississippi Valley Medical Society. Page xi, issue of July 14.

OCTOBER 11-15. American Society of Clinical Pathologists. Drake Hotel, Chicago.

OCTOBER 24-26. National Gastroenterological Association. Page 251.

OCTOBER 24-28. American Public Health Association. Page 251.

NOVEMBER 2. New England Obstetrical and Gynecological Society. Hotel Somerset, Boston.

NOVEMBER 2-5. Pan-American Congress of Pediatrics. Page 251.

NOVEMBER 3-5. American Association of Blood Banks. Page xi, issue of June 16.

NOVEMBER 7-9. National Society for Crippled Children and Adults. Page 184, issue of July 28.

NOVEMBER 7-12. International College of Surgeons. Page 251.

NOVEMBER 14-17. American Academy of Pediatrics. Page 251.

FEBRUARY 20-23. American Academy of General Practice. Notice above.

CALENDAR OF BOSTON DISTRICT FOR THE WEEK BEGINNING THURSDAY, AUGUST 18

FRIDAY, AUGUST 19

*9:00 a.m.-12:00 m. Combined Medical and Surgical Staff Rounds. Peter Bent Brigham Hospital.

*1:30 p.m. Tumor Clinic. Out-Patient Department, Mt. Auburn Hospital, Cambridge.

MONDAY, AUGUST 22

*11:30 a.m.-12:15 p.m. Chest X-Ray Conference. South End Health Unit, 57 East Concord Street, Boston. Dr. Cleaveland Floyd in charge.

*12:15-1:15 p.m. Clinicopathological Conference. Main Amphitheater, Peter Bent Brigham Hospital.

TUESDAY, AUGUST 23

*12:15-1:15 p.m. Clinicoroentgenological Conference. Peter Bent Brigham Hospital.

*1:30-2:30 p.m. Pediatric Rounds. Burnham Memorial Hospital for Children, Massachusetts General Hospital.

WEDNESDAY, AUGUST 24

*12:00 m.-1:00 p.m. Clinical Conference. (Children's Hospital.) Amphitheater, Peter Bent Brigham Hospital.

*Open to the medical profession.



When summer brings green apple days

And the children are running both ways,

Dr. Wise shortly finds

A stout potion that binds—

In the ads that the Journal *displays.*

2